

IMAGES IN INTERVENTION

# Combined Transcatheter Treatment of Ventricular Septal Rupture and Mitral Regurgitation After an Acute Myocardial Infarction

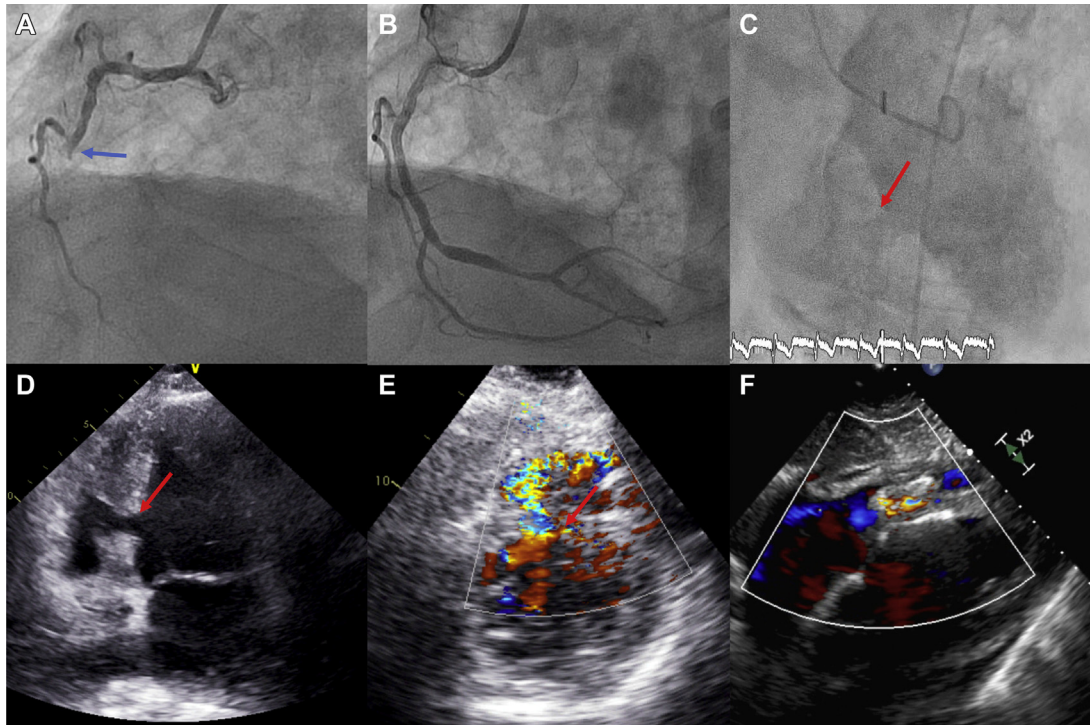


Tomás Benito-González, MD,<sup>a</sup> Rodrigo Estevez-Loureiro, MD, PhD,<sup>a</sup> Carmen Garrote-Coloma, MD, PhD,<sup>a</sup> David Alonso-Rodríguez, MD, PhD,<sup>a</sup> Laura Romero-Roche, MD,<sup>a</sup> Javier Gualis, MD, PhD,<sup>b</sup> Armando Perez de Prado, MD, PhD,<sup>a</sup> Felipe Fernandez-Vazquez, MD, PhD<sup>a</sup>

An 85-year-old man was admitted to our institution with an inferior acute myocardial infarction treated with primary angioplasty with drug-eluting stent implantation in the mid right coronary artery (Figure 1A). In the following 48 h, the patient presented signs of acute heart failure. Transthoracic echocardiography showed a moderately depressed LVEF, a ventricular septal rupture at the midposterior septum and severe ischemic mitral regurgitation as mechanical complications after the acute myocardial infarction (Figures 1C to 1E). Cardiac surgery was not an option, because of prohibitive perioperative risk. The patient was stabilized, and deferred percutaneous closure of the ventricular septal rupture was performed on the sixth day of hospitalization. An Amplatzer device (St. Jude Medical,

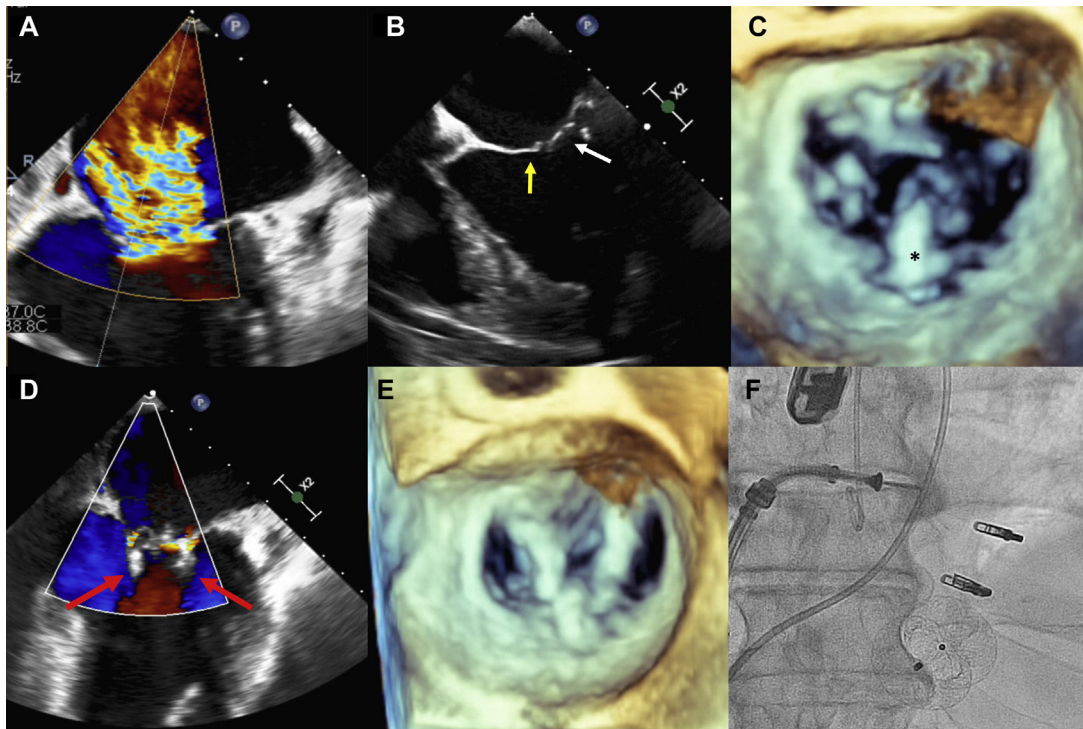
St. Paul, Minnesota) for post-myocardial infarction ventricular septal rupture (22 mm) was implanted through an arteriovenous loop with a nonsignificant residual shunt (Figure 1F) and reduced pulmonary/systemic flow ratio from 3.9 to 1.7. Hemodynamic improvement after the procedure allowed the patient to be discharged in stable condition. Two weeks later, percutaneous mitral valve repair was performed with the MitraClip system (Abbott Vascular, Santa Clara, California). Two significant jets were identified, with a severe calcification at the P2 segment (Figures 2A to 2C). Two clips were successfully deployed, leading to trace residual mitral regurgitation (Figures 2D to 2F). The patient was discharged uneventfully and remained in New York Heart Association functional class I at 3-month follow-up.

From the <sup>a</sup>Department of Cardiology, Hospital of León, León, Spain; and the <sup>b</sup>Department of Cardiovascular Surgery, Hospital of León, León, Spain. Dr. Estevez-Loureiro is a proctor for the MitraClip; and has received a grant from Abbott Vascular. All other authors have reported that they have no relationships relevant to the contents of this paper to disclose.

**FIGURE 1** Coronary Intervention and Ventricular Septal Rupture Closure

**(A,B)** Angiography showing occlusion of the mid right coronary artery (**blue arrow**) and result after percutaneous coronary intervention. **(C to E)** Ventriculography and transthoracic echocardiography showing a ventricular septal rupture at the midposterior septum (**red arrow**) with left-to-right shunt. **(F)** Result after percutaneous closure.

**FIGURE 2** Percutaneous Mitral Valve Repair Procedure



(A,B) Transesophageal echocardiogram showing severe mitral regurgitation with restriction of the posterior mitral leaflet (**white arrow**) and pseudoprolapse of the anterior leaflet (**yellow arrow**). (C) Severe calcification at P2 (**asterisk**). (D) Mild mitral regurgitation after placement of 2 clips. (E) Three-dimensional transthoracic echocardiogram with 3-hole mitral valve opening. (F) Final fluoroscopy with all devices.

**ADDRESS FOR CORRESPONDENCE:** Dr. Rodrigo Estevez-Loureiro, Hospital of León, Department of Cardiology, Altos de Nava SN, 24071 León, Spain.  
E-mail: [roiestevez@hotmail.com](mailto:roiestevez@hotmail.com).

**KEY WORDS** acute mitral regurgitation, acute myocardial infarction, mechanical complications, ventricular septal rupture