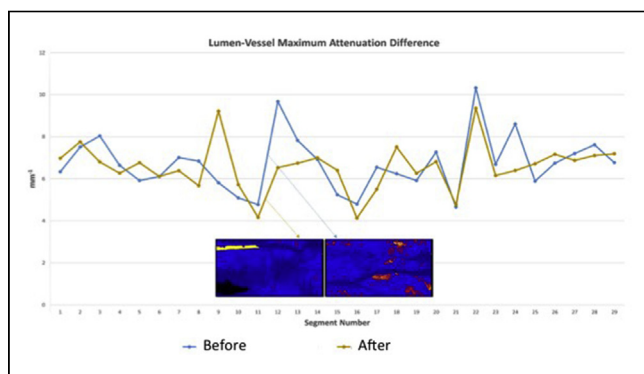


systemic inflammation. Macrophages are abundant in culprit lesion/ vessels and play a major role in the development of atherosclerosis and promotion of plaque vulnerability. The purpose of this study is, therefore, to investigate the change of bright spots signal detection by OCT in segments adjacent to culprit lesions.

METHODS A total of 29 non-culprit segments from 15 patients with ST-elevation myocardial infarction (STEMI) who had serial image acquisition at baseline and immediately after the percutaneous coronary intervention (PCI) by OCT were included. The pre- and post-stenting runs were exactly matched using anatomical landmarks as references for each patient. We applied an OCT bright spot quantitative algorithm which identifies a variety of plaque components. The light intensity, attenuation and backscattering data of bright spots within the most superficial 250 μm of the vessel wall were measured.

RESULTS Although a change in the bright spot density was witnessed (Figure), there was no significant difference observed in pre- and post-procedural maximum light intensity, attenuation, and backscattering (p=0.2196, 0.4147, 0.8249; respectively).

CONCLUSION While the variability of bright spots/macrophages detection in non-culprit segments by OCT after PCI could represent a true biological observation in the setting of the inflammatory response seen in STEMI patients, it could also be an artifact that is essential to be recognized in order to avoid inappropriate image interpretation.



CRT-300.05
Impact of Intravascular Imaging Methods for Optimal Scaffold Implantation Reducing Thrombosis After Absorb Bvs in a Real World Setting: Identification of Factors Related to Stent Failure



Sergio G. Tarbine, Costantino R. Costantini, Costantino O. Costantini, Marcelo F. Santos, Daniel Anibal Zanuttini, Rafael Macedo, Marco A. Denk
 Hospital Cardiologico Costantini, Curitiba, Brazil

BACKGROUND Recently, bioresorbable vascular scaffolds (BVS) were related to an unexpected high incidence of thrombosis. The aim of this study was to analyze in a single center experience, the impact of intravascular imaging (intravascular ultrasound-IVUS; optical coherence tomography-OCT) identifying and treating mechanical factors related to stent failure that would act as possible predictors of thrombosis and MACE.

METHODS Between 11/2014 and 10/2016, consecutive unselected patients (pts.) were treated with one or more Absorb BVS. Predilatation before stent deployment and post dilatation, IVUS and OCT were used in 99% of cases. Identified mechanical factors possibly related with stent failure were: stent malapposition, wall hematoma, stent underexpansion, border dissection, device fracture, thrombus and/or plaque protrusion. Customized measures were taken for each case. All pts. are under clinical follow up.

RESULTS 100 pts. (88% male, mean age 58,1 yo) were included in this analysis. Baseline characteristics show real world population (31% diabetics, 52% multivessel ds). A total of 141 lesions were treated (LAD 74%), being B/C class in 60%. Median SYNTAX score was 14,2±8.8. 190 Absorb BVS were implanted (1,9 stent/pt.). Further intervention following intravascular imaging with balloon optimization and/or new stent implantation was necessary in 16% of cases because of previously described mechanical factors, not seen by angiography. After optimal result was obtained, oral anticoagulation in addition to

double antiplatelet therapy was indicated during the first 45 days in those pts having thrombus and/or plaque protrusion in OCT analysis. With 100% procedure success, 100% completed 1 yr follow up. MACE shows definite/probable scaffold thrombosis in 0%, with 4% TLR and 3% TVR.

CONCLUSION The follow up analysis of this cohort of patients is showing no thrombosis so far, in a real world all comers setting. Detection of implantation defects by intravascular imaging and not seen by angiography, followed by customized treatment with balloon/stent, seems to be responsible for the low adverse event rate, caused in these pts., by focal restenosis.

OTHER

CRT-300.06
Myocardial Bridging is Underreported during Coronary Angiography



Marinos Charalambous,¹ John Makaryus,¹ Elpidoforos Soteriades,² Savvas Constantinides,² Christos Christou²
¹Zucker School of Medicine at Hofstra Northwell, Queens Village, NY; ²American Heart Institute, Nicosia, Cyprus

BACKGROUND Myocardial bridging (MB) is an anatomical variant of the coronary arteries in which a portion of the coronary artery takes an intramuscular course and becomes covered by a “bridge” of myocardium. While usually asymptomatic, MB may be responsible for chest pain, acute coronary syndromes, left ventricular dysfunction and arrhythmias. The prevalence of MB reported on autopsy studies and on coronary computed tomography (CCT) varies but the mean prevalence is approximately 25%. There are very few studies reporting the prevalence of MB based on coronary angiography (CA). Our aim is to identify the epidemiological and morphological characteristics of MB based on our CA registry.

METHODS Data from 6779 angiograms performed between January 2006 and December 2015 were analyzed. All patients reported to have MB on CA were identified. Baseline characteristics, indications for CA and all procedural information were collected through a computerized database.

RESULTS Among 6779 CA performed, only 22 cases of MB were reported (prevalence 0.3%). Mean age was 58.8 years (range 38-75 years). Only 2/22 (9%) were females. The indications for CA were: chest pain [9/22 (41%)], abnormal stress test [9/22 (41%)], abnormal CCT [(2/22 (9%)], acute MI [2/22 (9%)]. 18 out of 22 patients (82%) had MB in mid-LAD. 4 out of 22 patients (18%) had MB in distal LAD. 5 out of 22 patients (23%) had obstructive CAD in addition to MB. 12 out of 22 (55%) patients had no CAD and 5 out of 22 (23%) had non-obstructive CAD.

CONCLUSION Based on our study, Myocardial Bridging is significantly underdiagnosed (reported prevalence 0.3%) during coronary angiography compared to the rates reported on CCT or autopsy studies (mean prevalence 25%). MB can have great clinical significance, especially in symptomatic patients and every effort should be made to report such lesions during coronary angiography.

CRT-300.07
Quantification and Depth Resolution of Lipid Core Plaques by Intravascular Photoacoustic and Ultrasound Dual-Modality Imaging



Ayeeshik Kole,¹ Yingchun Cao,² Jie Hui,² Islam Bolad,¹ Mouhamad Alloosh,¹ Ji-Xin Cheng,³ Michael Sturek¹
¹Indiana University School of Medicine, Indianapolis, IN; ²Purdue University Weldon School of Biomedical Engineering, West Lafayette, IN; ³Boston University Photonics Center, Boston, MA

BACKGROUND Current imaging tools lack sensitivity and depth resolution to accurately quantify lipid core content at different stages of disease. Here, we present an intravascular catheter which can produce co-registered images of morphology and depth-resolved lipid core content via ultrasound and photoacoustic modes, respectively.

METHODS We performed *in vivo* intravascular photoacoustic-ultrasound (IVPA-US) imaging of the iliac arteries of Ossabaw swine with dyslipidemia (n=3) and lean control swine (n=3) to investigate sensitivity to detect early atherosclerosis. We repeated imaging *ex vivo* with near-infrared spectroscopy (NIRS) for comparison to IVPA-US and histology. To investigate late-stage atherosclerosis, we