

## IMAGES IN INTERVENTION

## Very Late Restenosis of a BVS Implanted in a Degenerated Saphenous Vein Graft

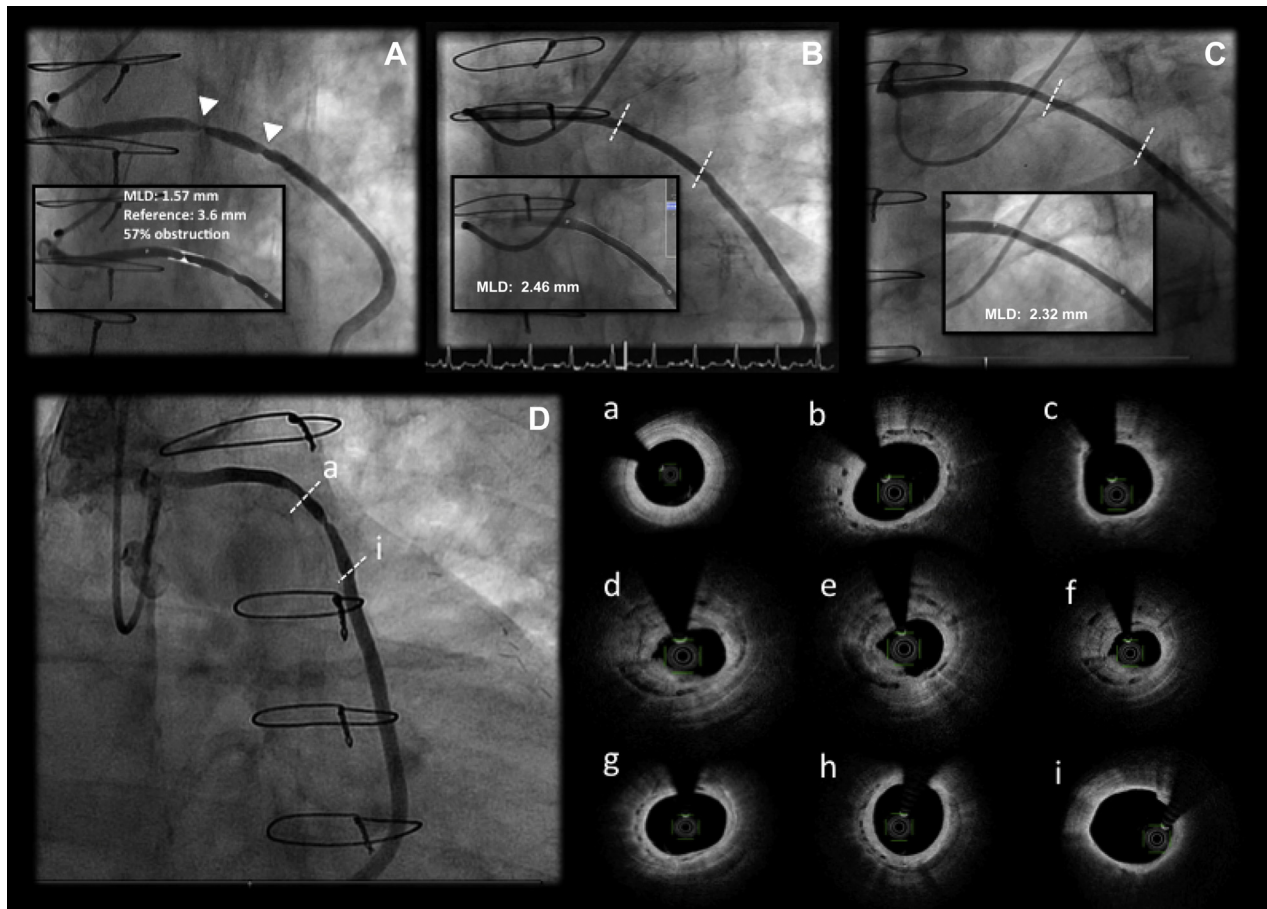
Juan Gabriel Córdoba-Soriano, MD, Antonio Gutiérrez-Díez, MD, Arsenio Gallardo López, MD, Jesús Jiménez-Mazuecos, MD

The use of bioresorbable vascular scaffolds (BVS) in aortocoronary grafts has been scarcely reported in the literature, with some isolated cases (1-3) and a unicentric series of 6 cases (4). In pivotal trials, saphenous vein grafts (SVGs) were also excluded, and have been poorly represented in large registries. However, in recent times, great concern has been raised about the increase of target lesion failure with these devices, which seem to occur at the time of the most potential benefit expected, at long term.

A 68-year-old diabetic man with history of aortocoronary revascularization surgery in 1989 and 2001, first with an SVG to the left anterior descending artery (LAD) and an SVG to first obtuse marginal branch, and second with the left internal mammary artery to the LAD and an SVG to second obtuse marginal branch, with permeability of all grafts except SVG-first-obtuse-marginal-branch in 2006, presented in 2013 with unstable angina for a critical stenosis in the body of the SVG to second obtuse marginal branch (Figure 1A, Online Video 1). A 3.5 mm × 28 mm BVS (ABSORB, Abbott Vascular, Santa Clara, California) was implanted according to the so-called pre-dilatation, proper

sizing and post-dilatation technique with an excellent angiographic result (Figure 1B, Online Video 2). An angiographic control performed 17 months later for atypical chest pain showed sustained success of the device with a late luminal loss of 0.14 mm (Figure 1C, Online Video 3). At 47 months, new catheterization was performed due to unstable angina that showed a severe focal restenosis (Figure 1D, Online Video 4). The optical frequency domain imaging (Figures 1a to 1i, Online Video 5) showed incomplete BVS resorption, signs of neointimal hyperplasia as high-intensity homogeneous tissue (Figures 1b, 1g, and 1h), signs of neoatherosclerosis with presence of lipid tissue with high posterior attenuation (Figure 1c), and layered restenosis with heterogeneous tissue and irregular luminal border at the point of greatest obstruction (Figures 1d to 1f). It is possible that a different resorption velocity of the BVS in SVG triggered this very late restenosis, the first reported in this location.

**ADDRESS FOR CORRESPONDENCE:** Dr. Juan Gabriel Córdoba-Soriano, Hermanos Falcó 37, 02008, Albacete, Spain. E-mail: [jgcorso.jgcs@gmail.com](mailto:jgcorso.jgcs@gmail.com).

**FIGURE 1** Degenerated Saphenous Vein Graft Treated With Bioresorbable Vascular Scaffold and Very Late Restenosis

(A) Degenerated saphenous vein graft with 2 stenoses (arrowheads) (Online Video 1); (B) saphenous vein graft treated with a  $3.5 \times 28$  mm ABSORB bioresorbable vascular scaffold (Abbott Vascular, Santa Clara, California) (Online Video 2); (C) angiographic control at 17 months (Online Video 3); (D) severe focal restenosis at 47 months (Online Video 4). (a-i) Optical frequency domain imaging from proximal to distal edges of the scaffold (Online Video 5). MLD = minimal lumen diameter.

## REFERENCES

- Ong PJL, Jafary FH, Ho HH. "First-in-man" use of bioresorbable vascular scaffold in saphenous vein graft. *EuroIntervention* 2013;9:165.
- Yew KL. Novel use of absorb bioresorbable vascular scaffold and STENTYS self-apposing coronary stent for complex saphenous vein grafts intervention. *Int J Cardiol* 2014;177:e184-5.
- Roleder T, Parma Z, Smolka G, Ochala A, Wojakowski W. Optical coherence tomography imaging of everolimus-eluting bioresorbable vascular scaffold implanted into coronary vein graft at 3-month follow-up. *Eur Heart J* 2014;35:2207.
- Roleder T, Wanha W, Smolka G, Zimoch J, Ochala A, Wojakowski W. Bioresorbable vascular scaffolds in saphenous vein grafts (data from OCTOPUS registry). *Postep. Kardiol Interwencyjnej* 2015;11:323-6.

**KEY WORDS** BVS, restenosis, saphenous vein graft

**APPENDIX** For supplemental videos and their legends, please see the online version of this article.