

IMAGES IN INTERVENTION

Giant Saphenous Vein Graft Aneurysm Causing Compression of the Left Ventricle



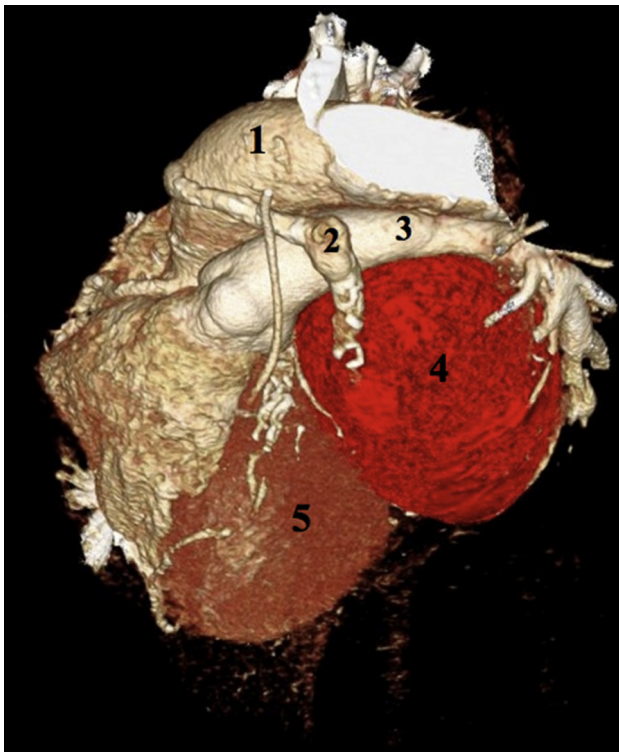Nauman Siddiqi, MD, John Wang, MD

A 64-year-old man with a history of coronary artery bypass graft surgery and mechanical aortic valve replacement in 1995 presented with unstable angina and volume overload. He

underwent cardiac catheterization, which revealed a giant saphenous vein graft aneurysm (SVGA) arising from the left circumflex artery (LCX) graft (Online Video 1). We performed computed tomography with 3-dimensional reconstruction, which revealed an 11 × 9 × 9-cm SVGA 8.5 cm distal to the origin of the ascending aorta with a mass effect on the left pulmonary artery, left atrium, and the left ventricle. His native LCX was draped over the SVGA (Figure 1). The contents of the SVGA were high-density blood products.

He was deemed high risk for surgery and underwent successful percutaneous coil embolization. A total of 7 Interlock coils (Boston Scientific, Marlborough, Massachusetts) were deployed (two 22 × 60 cm, one 20 × 50 cm, one 18 × 50 cm, three 14 × 50 cm) in the smaller aneurysmal area in the SVG just before the giant aneurysm via a Direxion catheter (Boston Scientific). Immediately after coiling, the SVG had slow Thrombolysis In Myocardial Infarction (TIMI) flow grade I past the coils, which was thought to be an acceptable result (Online Video 2). A chest radiograph post-embolization revealed the SVGA seen well as an anterior mediastinal mass in the lateral projection (Figure 2, red arrow) and the radiopaque coils (Figure 2, black arrow). The patient returned to the cardiac catheterization lab for a second look graft angiography approximately 3 weeks later. The SVG to the LCX was now totally occluded with a TIMI flow grade of 0 beyond the coils (Online Video 3).

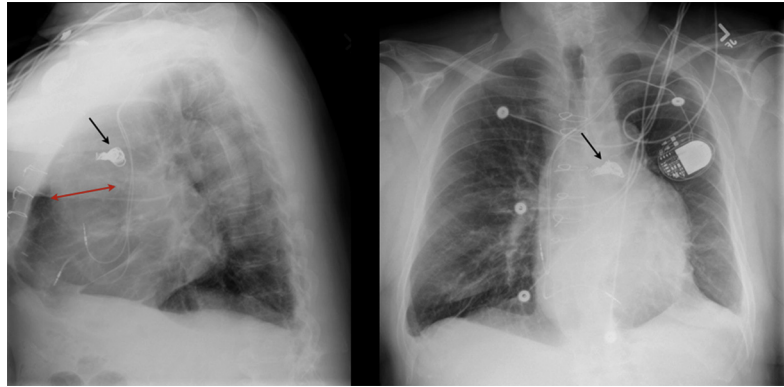
FIGURE 1 3-Dimensional Computed Tomography



1 = aorta; 2 = saphenous vein graft; 3 = pulmonary artery; 4 = saphenous vein graft aneurysm; 5 = left ventricle (Online Videos 1, 2 and 3).

From the MedStar Heart and Vascular Institute at MedStar Union Memorial Hospital, Baltimore, Maryland. Dr. Wang is on the Speakers' Bureau and Advisory Board of Boston Scientific; and on the Advisory Board of Abbott Vascular. Dr. Siddiqi has reported that he has no relationships relevant to the contents of this paper to disclose.

Manuscript received January 12, 2016; accepted January 20, 2016.

FIGURE 2 Posteroanterior and Lateral Chest Radiographs

Red arrow indicates saphenous vein graft aneurysm; **black arrow** indicates coils.

REPRINT REQUESTS AND CORRESPONDENCE: Dr. Nauman Siddiqi, Cardiac Cath Lab, MedStar Union Memorial Hospital, 201 East University Parkway, Baltimore, Maryland 21218. E-mail: nauman.h.siddiqi@medstar.net.

KEY WORDS aneurysm, graft, saphenous, percutaneous coil embolization

APPENDIX For supplemental videos, please see the online version of this article.