

IMAGES IN INTERVENTION

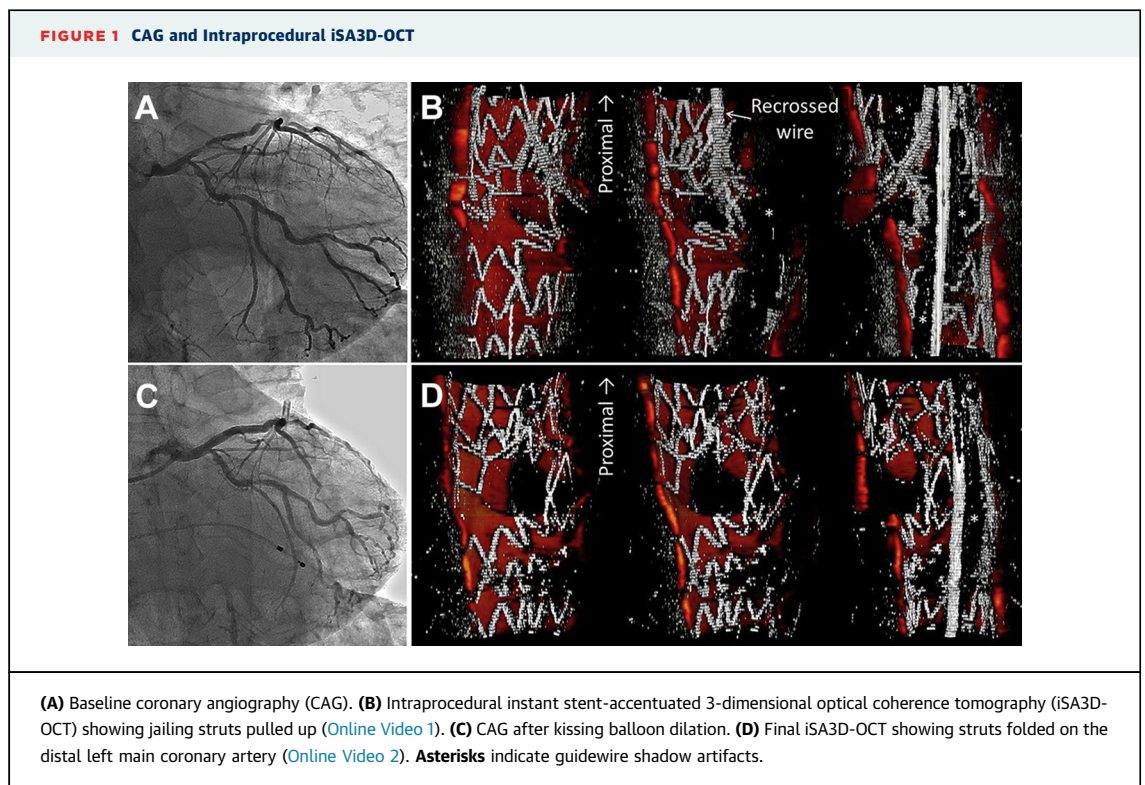
Instant Stent-Accentuated 3-Dimensional Optical Coherence Tomography of Struts Pulled Up by Pulling Stuck Wire and Folded by Kissing Balloon Dilation



Fumiaki Nakao, MD, PhD

Percutaneous coronary intervention was performed on a 60-year-old man for stenoses of the left anterior descending coronary artery (LAD) (Figure 1A). The LAD was stented with 2 biolimus-eluting stents (BES) (Nobori, Terumo,

Tokyo, Japan). The left main coronary artery (LM)-LAD was stented with a 2-link 10-crown BES. When followed by rewiring to the left circumflex artery (LCx), the recrossed wire became stuck and was freed by pulling strongly. According to intraprocedural instant



From the Department of Cardiology, Yamaguchi Grand Medical Center, Yamaguchi, Japan. Dr. Nakao has reported that he has no relationships relevant to the contents of this paper to disclose.

Manuscript received December 24, 2014; accepted January 15, 2015.

stent-accentuated 3-dimensional optical coherence tomography (iSA3D-OCT) (1,2), reconstructed in about 30 s from OCT (Dragonfly JP, St. Jude Medical, St. Paul, Minnesota) and imported to an off-line workstation by freeware ImageJ 1.47v (National Institutes of Health, Bethesda, Maryland) with self-made macroprograms, struts jailing the LCx ostium were pulled up by pulling the wire (Figure 1B, Online Video 1). After kissing balloon dilation (Figure 1C), final iSA3D-OCT showed struts folded on the distal LM (Figure 1D, Online Video 2). Moderate stenosis of the ostial LCx

was not stented because of folded struts and floating struts.


Confirmation by intraprocedural iSA3D-OCT is important. Final iSA3D-OCT gives us important information about the selection of strategies for the side-branch lesion.

REPRINT REQUESTS AND CORRESPONDENCE: Dr. Fumiaki Nakao, Department of Cardiology, Yamaguchi Grand Medical Center, 77 Ohsaki Hofu, Yamaguchi 747-8511, Japan. E-mail: nakao-ymghp@umin.ac.jp.

REFERENCES

1. Nakao F, Ueda T, Nishimura S, et al. Novel and quick coronary image analysis by instant stent-accentuated three-dimensional optical coherence tomography system in catheterization laboratory. *Cardiovasc Interv Ther* 2013;28:235-41.
2. Nakao F. Instant stent-accentuated 3-dimensional optical coherence tomography of a bifurcation lesion treated with reverse minimum overlapping culotte stenting. *J Am Coll Cardiol Intv* 2014;7:e121-2.

KEY WORDS bifurcation PCI, stent deformation, 3D-optical coherence tomography

 **APPENDIX** For supplemental videos, please see the online version of this article.