

## IMAGES IN INTERVENTION

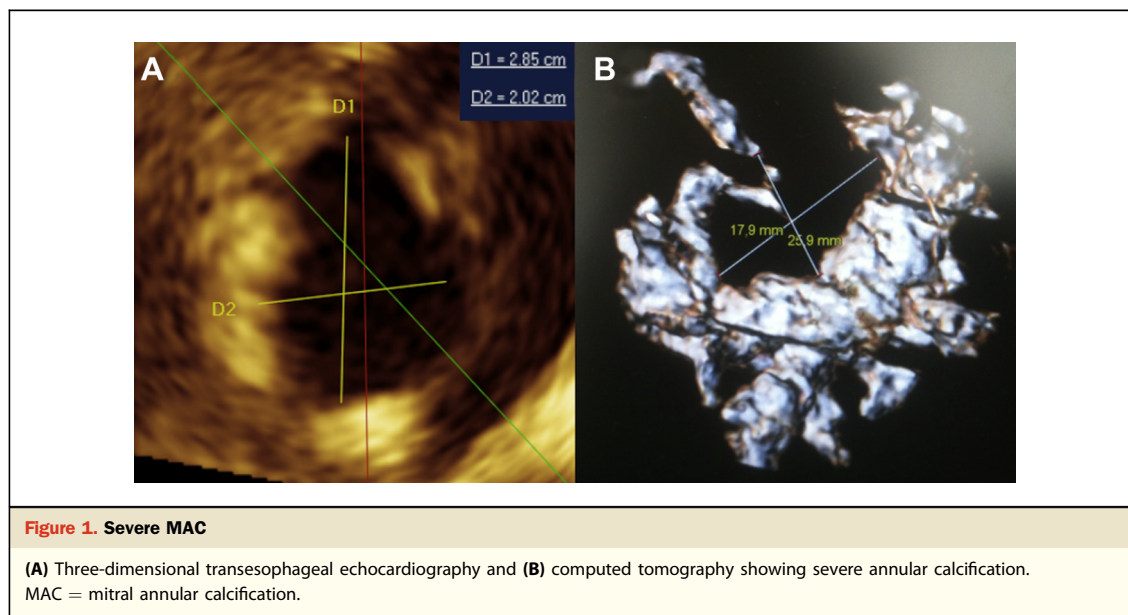
# Transseptal Transcatheter Mitral Valve Implantation for Severely Calcified Mitral Stenosis

Amir-Ali Fassa, MD,\* Dominique Himbert, MD,\* Eric Brochet, MD,\* Jean-Pol Depoix, MD,† Adrian P. Cheong, MD,\* Soleiman Alkhoder, MD,‡ Patrick Nataf, MD,‡ Alec Vahanian, MD\*

Paris, France

A 72-year-old woman, with prior aortic valve replacement and tricuspid annuloplasty, was referred for heart failure. Echocardiography showed mitral stenosis (mean gradient 12 mm Hg, area 0.8 cm<sup>2</sup>) with severe mitral annular calcification (MAC) (Fig. 1A). Computed tomography demon-

strated a nearly circumferential distribution of the calcification (Fig. 1B). heart team planned transcatheter mitral valve implantation (TMVI) through a transseptal (TS) approach, which was considered as less invasive than the transapical route. The decision was also based on experience from our center with TS interventions (1). The procedure was performed



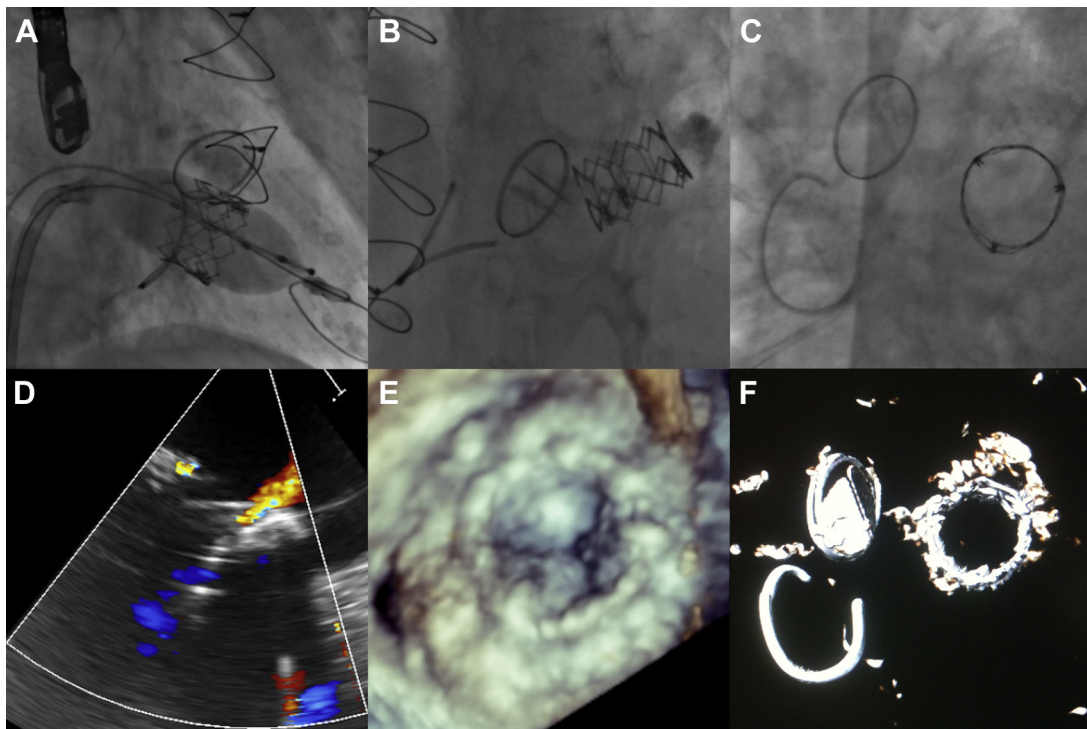
strated a nearly circumferential distribution of the calcification (Fig. 1B). Because of the high surgical risk (Logistic EuroSCORE 17%, EuroSCORE II 10%, STS score 11%), severe MAC, and long-term corticosteroid therapy for rheumatoid arthritis, the

from the right femoral vein, under general anesthesia and guidance by transesophageal echocardiography (TEE). After TS puncture and dilation of the atrial septum with a 14-mm balloon, an Amplatzer Extra-Stiff guidewire (Cook Medical,

From the \*Department of Cardiology, Bichat-Claude-Bernard Hospital, Assistance Publique-Hôpitaux de Paris, Université Paris VII, Paris, France; †Department of Anesthesiology, Bichat-Claude-Bernard Hospital, Assistance Publique-Hôpitaux de Paris, Université Paris VII, Paris, France; and the ‡Department of Cardiac Surgery, Bichat-Claude-Bernard Hospital, Assistance Publique-Hôpitaux de Paris, Université Paris VII, Paris, France. Dr. Himbert is a proctor for Edwards Lifesciences and

Medtronic; and is a consultant for Edwards Lifesciences. Dr. Nataf is a proctor for Edwards Lifesciences. Dr. Vahanian has received speaker's fees from Edwards Lifesciences. The other authors have reported that they have no relationships relevant to the contents of this paper to disclose.

Manuscript received October 22, 2013; revised manuscript received November 30, 2013; accepted December 10, 2013.



**Figure 2. Transseptal Transcatheter Mitral Valve Implantation**

(A) Implantation of a 26-mm SAPIEN XT valve (Online Video 1). (B and C) Perpendicular and en face views (Online Videos 2 and 3). (D) Color Doppler transesophageal echocardiography (TEE) showing mild paravalvular regurgitation (Online Video 4). Post-implantation 3-dimensional TEE (E) (Online Video 5) and computed tomography (F).

Bloomington, Indiana) was positioned in the left ventricle. A 26-mm SAPIEN XT valve (Edwards Lifesciences, Irvine, California) was then successfully implanted within the mitral annulus, using slow inflation during rapid ventricular pacing (Fig. 2, Online Videos 1, 2, 3, 4, and 5). TEE showed mild paravalvular regurgitation and a mean gradient of 4 mm Hg. Hospital stay was uneventful, and the patient was discharged 7 days after the intervention.

TMVI has only been described through a transapical or an open left atrial approach (2–4). This first report suggests that the TS route may represent a less invasive approach for this novel technique in selected patients with severely calcified mitral stenosis at high risk for surgery. The decision to perform this intervention should be on the basis of a critical assessment by the heart team.

**Reprint requests and correspondence:** Dr. Dominique Himbert, Department of Cardiology, Bichat Hospital, 46 rue Henri-Huchard, 75018 Paris, France. E-mail: [dominique.himbert@bch.aphp.fr](mailto:dominique.himbert@bch.aphp.fr).

#### REFERENCES

1. Himbert D, Descoutures F, Brochet E, et al. Transvenous mitral valve replacement after failure of surgical ring annuloplasty. *J Am Coll Cardiol* 2012;60:1205–6.
2. Hasan R, Mahadevan VS, Schneider H, Clarke B. First in human transapical implantation of an inverted transcatheter aortic valve prosthesis to treat native mitral valve stenosis. *Circulation* 2013;128:e74–6.
3. Sinning JM, Mellert F, Schiller W, Welz A, Nickenig G, Hammerstingl C. Transcatheter mitral valve replacement using a balloon-expandable prosthesis in a patient with calcified native mitral valve stenosis. *Eur Heart J* 2013;34:2609.
4. Astarci P, Glineur D, De Kerchove L, El Khoury G. Transcatheter valve used in a bailout technique during complicated open mitral valve surgery. *Interact Cardiovasc Thorac Surg* 2013;17:745–7.

**Key Words:** calcification ■ mitral stenosis ■ transcatheter heart valve ■ transseptal.

#### ▶ APPENDIX

For accompanying videos, please see the online version of this paper.