

Recent studies have suggested that fractional flow reserve (FFR)-guided percutaneous coronary intervention (PCI) is associated with reduced major adverse cardiac events in patients with multivessel coronary artery disease (1-3). Furthermore, FFR >0.75 to 0.80 is a strong predictor of excellent survival and low event rates in patients with intermediate left main (LM) disease, making it useful to identify patients in whom deferral of revascularization is associated with favorable clinical outcomes (4-9).

Because angiographic assessment of LM stenosis severity is not accurate (10,11), there have been attempts to find intravascular ultrasound (IVUS) measurements that correspond to the functional significance and clinical outcomes and to integrate morphological, physiological, and long-term follow-up data. The suggested minimal lumen area (MLA) cutpoint has varied from 5.9 to 9.6 mm² for identifying significant LM disease; therefore, the optimal cutoff value and its accuracy remain debatable (7,12,13). The aim of this study was to determine the best IVUS criteria for predicting physiological significance of intermediate isolated LM lesions with FFR as the standard.

Methods

Study population. Between January 2010 and April 2011, coronary angiography identified de novo LM disease in 145 patients. After excluding patients with regional wall motion abnormality, significant distal lesions (angiographic diameter stenosis [DS] >50% within the left anterior descending artery [LAD] or left circumflex artery, either sequential or tandem involvement), myocardial infarction, or angiographic thrombi-containing lesions and cases in which the IVUS-imaging catheter failed to cross the lesion due to tight stenosis or tortuosity, we identified 55 consecutive patients (31 stable angina and 24 unstable angina) with an isolated LM lesion of 30% to 80% angiographic DS on visual estimation. These patients underwent IVUS and invasive physiological assessment before intervention. Treatment strategies were at the discretion of the operator. This study was approved by the institutional review board, and all patients provided written informed consent.

Angiographic analysis. Qualitative and angiographic analysis was done by standard techniques with automated edge-detection algorithms (CASS-5, Pie-Medical, Maastricht, the Netherlands) in the angiographic analysis center of the CardioVascular Research Foundation, Seoul, Korea. Minimal lumen diameter, DS, and lesion length were measured in the least foreshortened view. Lesion location was based on the site of minimal lumen diameter within the LM.

FFR measurement. "Equalization" was performed with the guidewire sensor positioned at the guiding catheter tip. Then, the 0.014-inch pressure guidewire (Radi, St. Jude Medical, Uppsala, Sweden) was advanced into the coronary artery and positioned \geq 3 cm distal to the LM lesion into

the LAD or left circumflex artery, depending on which was least diseased distally. The FFR was measured at maximal hyperemia induced by intravenous adenosine infusion, administered at 140 to 180 μ g/kg/min through a central vein. Hyperemic pressure pullback recordings were performed as described previously (8,14,15). In patients with an ostial LM stenosis, care was taken to pull the guiding catheter out of the LM during FFR assessment.

IVUS imaging and analysis. After FFR assessment, LAD-pullback IVUS imaging was performed after intracoronary administration of 0.2 mg nitroglycerin with motorized transducer pullback (0.5 mm/s) and a commercial scanner (Boston Scientific/SCIMED, Minneapolis, Minnesota) consisting of a rotating 40-MHz transducer within a 3.2-F imaging sheath. With computerized planimetry (Echo Plaque 3.0, Indec Systems, Mountain View, California), off-line quantitative IVUS analysis was performed as previously described (16) in a core laboratory at the Asan Medical Center. At the site of the smallest lumen within the LM segment above the carina, MLA and external elastic membrane (EEM) area were measured. Plaque burden (PB) at the MLA site was calculated as: (EEM area - lumen area)/EEM area \times 100%.

Statistical analysis. All statistical analyses were performed with SAS (release 9.1, SAS Institute, Inc., Cary, North Carolina) or SPSS (version 10.0, SPSS, Inc., Chicago, Illinois). All values are expressed as mean \pm 1 SD (continuous variables) or as count and percentage (categorical variables). Continuous variables were compared by use of the nonparametric Mann-Whitney test or Kruskal-Wallis test; categorical variables were compared with the chi-square statistic or Fisher exact test.

Stepwise multiple linear regression analysis was performed to assess the independent predictors for FFR as a continuous variable, including the variables, such as lesions location, MLA, PB, angiographic DS, lesion length, and presence of plaque rupture. To ascertain independent predictors of FFR as binary variable (FFR <0.80 and FFR <0.75), multivariable logistic regression analysis was also performed.

To determine FFR <0.80 and FFR <0.75, receiver-operator characteristic (ROC) curves were analyzed to assess the best cutoff values of IVUS parameters that minimize the distance between the curve and the upper corner, with

Abbreviations and Acronyms

AUC = area under the curve

CI = confidence interval

DS = diameter stenosis

EEM = external elastic membrane

FFR = fractional flow reserve

IVUS = intravascular ultrasound

LAD = left anterior descending artery

LM = left main coronary artery

MLA = minimal lumen area

PB = plaque burden

PCI = percutaneous coronary intervention

ROC = receiver-operator characteristic

Table 1. Baseline Clinical Characteristics in 55 Patients With LM Disease

	Total (N = 55)	FFR <0.80 (n = 26)	FFR ≥0.80 (n = 29)	p Value
Age, yrs	60 ± 12	58 ± 11	61 ± 12	0.287
Male	41 (75%)	21 (81%)	20 (69%)	0.245
Ejection fraction, %	62 ± 6	62 ± 7	60 ± 5	0.329
Diabetes	16 (29%)	8 (31%)	8 (28%)	0.514
Hypertension	27 (49%)	14 (54%)	13 (45%)	0.346
Smoking	31 (56%)	17 (65%)	14 (48%)	0.157
Hyperlipidemia	40 (73%)	20 (77%)	20 (69%)	0.361
Previous PCI	10 (18%)	4 (15%)	6 (21%)	0.391
Renal failure	2 (4%)	1 (4%)	1 (4%)	0.439
Clinical manifestation				
Stable angina	31 (56%)	14 (54%)	17 (58%)	0.671
Unstable angina	24 (44%)	12 (46%)	12 (41%)	

Values are mean ± SD or n (%). Fractional flow reserve (FFR) <0.80 vs. FFR ≥0.80.
LM = left main coronary artery; PCI = percutaneous coronary intervention.

MedCalc (MedCalc Software, Mariakerke, Belgium). The sensitivity, specificity, positive predictive value, and negative predictive value with 95% confidence intervals (CIs) were obtained. A p value <0.05 was considered statistically significant.

Results

Clinical and angiographic characteristics. The clinical characteristics and angiographic findings in 55 patients with 55 coronary lesions are summarized in Tables 1 and 2. The

lesion location was LM ostium in 27 (49%) lesions and LM shaft in 10 (18%) lesions. In the remaining 18 (33%) distal LM lesions, Medina classification was 1,1,1 in 3 lesions; 1,1,0 in 4 lesions; 1,0,0 in 9 lesions; and 1,0,1 in 2 lesions. Quantitative coronary angiographic DS was $47.7 \pm 11.6\%$ (range 30% to 78%). Overall, 26 (47%) lesions had FFR <0.80, and 19 (35%) lesions had FFR <0.75 at maximum hyperemia. There was a trend for a worse angiographic DS in the lesions with FFR <0.80 versus FFR ≥0.80 ($50.5 \pm 12.6\%$ vs. $44.8 \pm 10.3\%$, $p = 0.070$); however, this did not reach statistical significance. There was no significant difference in FFR between stable angina versus unstable angina presentation (0.80 ± 0.08 vs. 0.81 ± 0.11 , $p = 0.797$) or patients with diabetes versus without diabetes (0.81 ± 0.10 vs. 0.79 ± 0.08 , $p = 0.377$).

IVUS findings. Table 2 summarizes the IVUS findings. Plaque rupture was seen in 18 (33%) lesions, and the most frequent rupture sites were LM ostium and shaft locations (13 of 18 [77%]). The MLA and FFR were $5.6 \pm 1.9 \text{ mm}^2$ and 0.83 ± 0.10 in ostial LM lesions; $3.5 \pm 1.5 \text{ mm}^2$ and 0.79 ± 0.09 in shaft lesions; and $4.1 \pm 1.8 \text{ mm}^2$ and 0.77 ± 0.07 in distal LM lesions ($p = 0.008$ for MLA, and $p = 0.02$ for FFR among the 3 groups).

Determinants for FFR. The FFR at maximum hyperemia significantly correlated with IVUS-measured MLA within the LM ($r = 0.623$, $p < 0.001$), IVUS-measured PB within the LM ($r = -0.548$, $p < 0.001$), angiographic DS ($r = -0.449$, $p = 0.002$), and angiographic length of the lesion ($r = -0.292$, $p = 0.046$). Although there was no difference

Table 2. Quantitative Coronary Angiographic and IVUS Findings in 55 Intermediate LM Lesions

	Total (N = 55)	FFR <0.80 (n = 26)	FFR ≥0.80 (n = 29)	p Value*
Quantitative coronary angiography				
Angiographic ulceration	5 (11%)	3 (13%)	2 (8%)	0.601
Proximal reference diameter, mm	3.9 ± 0.6	3.8 ± 0.6	4.1 ± 0.6	0.174
Distal reference diameter, mm	3.5 ± 0.5	3.4 ± 0.4	3.7 ± 0.5	0.151
Interpolated diameter, mm	3.7 ± 0.5	3.6 ± 0.5	3.8 ± 0.4	0.063
Minimal lumen diameter, mm	2.0 ± 0.5	1.8 ± 0.5	2.1 ± 0.6	0.004
Diameter stenosis, %	47.7 ± 11.6	50.5 ± 12.6	44.8 ± 10.3	0.070
Lesion length, mm	10.8 ± 5.4	13.0 ± 5.2	8.8 ± 4.1	0.001
IVUS findings				
At MLA site within LM				
MLA, mm ²	4.9 ± 2.4	3.4 ± 1.2	6.3 ± 2.3	<0.001
EEM area, mm ²	17.8 ± 5.5	16.8 ± 3.6	18.7 ± 6.7	0.202
Plaque burden, %	69.3 ± 15.4	77.5 ± 10.8	61.9 ± 15.6	<0.001
At the LAD ostium				
MLA, mm ²	5.9 ± 2.3	5.6 ± 2.0	6.2 ± 2.6	0.396
EEM area, mm ²	13.5 ± 3.8	12.8 ± 3.0	14.1 ± 4.3	0.230
Plaque burden, %	57.0 ± 15.4	56.9 ± 13.0	57.1 ± 17.8	0.566

Values are n (%) or mean ± SD. *Fractional flow reserve (FFR) <0.80 vs. FFR ≥0.80.
EEM = external elastic membrane; IVUS = intravascular ultrasound; LAD = left anterior descending coronary artery; LM = left main coronary artery; MLA = minimal lumen area.

in the MLA between lesions with and without plaque rupture, FFR was significantly lower in 18 lesions with plaque rupture than 37 lesions without plaque rupture (0.76 ± 0.09 vs. 0.82 ± 0.09 , $p = 0.018$).

Multivariable linear and logistic regression analysis included MLA, PB, angiographic DS, lesion location, lesion length, and presence of plaque rupture. The independent determinants of FFR as a continuous variable were MLA (beta = 0.598, 95% CI: 0.017 to 0.040, $p < 0.001$) and plaque rupture (beta = -0.255, 95% CI: -0.088 to -0.005, $p = 0.038$). Table 3 shows the results of univariable analysis to predict an abnormal FFR as a dichotomous variable. The MLA within the LM was the only independent determinant for FFR <0.80 (adjusted odds ratio: 0.312, 95% CI: 0.164 to 0.593, $p < 0.001$) and for FFR <0.75 (adjusted odds ratio: 0.196, 95% CI: 0.076 to 0.501, $p = 0.001$).

Cutoff values of predictors for abnormal FFR. The IVUS MLA value within the LM (minimizing the distance between the curve and the upper corner of the graph) that best predicted FFR <0.80 was $<4.8 \text{ mm}^2$ (89% sensitivity, 83% specificity, area under the curve [AUC]: 0.90, 95% CI: 0.788 to 0.964, $p < 0.001$) (Fig. 1). The overall diagnostic accuracy was 86% (Fig. 2) with a CI of 2.9 to 5.2 mm^2 . In 23 (82%) of 28 lesions with an MLA $<4.8 \text{ mm}^2$, FFR was <0.80. Among 27 lesions with an MLA $\geq 4.8 \text{ mm}^2$, 3 (11%) had FFR <0.80, and only 1 (4%) had FFR <0.75 (Fig. 2). In addition, the cutoff value of PB to predict FFR <0.80 was $\geq 72\%$ (sensitivity 73%, specificity 79%, AUC: 0.79, 95% CI: 0.664 to 0.891, $p < 0.001$).

Furthermore, the IVUS-measured MLA that best predicted FFR <0.75, was $<4.1 \text{ mm}^2$ (95% sensitivity, 83% specificity, and AUC: 0.92, 95% CI: 0.810 to 0.976, $p < 0.001$). The overall diagnostic accuracy was 87% (Fig. 2) with a CI of 3.2 to 4.1 mm^2 . Among 31 lesions with an

MLA $\geq 4.1 \text{ mm}^2$, all but 1 (97%) lesion had FFR ≥ 0.75 , and that lesion had a plaque rupture. In addition, the cutoff value of PB to predict FFR <0.75 was $\geq 76\%$ (sensitivity 79%, specificity 80%, AUC: 0.84, 95% CI: 0.718 to 0.925, $p < 0.001$).

When subgroup analysis included only 37 lesions without plaque rupture, the cutoff value of the MLA for predicting FFR <0.75 was $<4.8 \text{ mm}^2$ with a sensitivity of 93% and a specificity of 86% (AUC: 0.935, $p < 0.001$). Conversely, in 18 lesions with plaque rupture, the MLA $<4.8 \text{ mm}^2$ predicted FFR <0.80 with a sensitivity of 83% and a specificity of 67%. In addition, the diagnostic accuracy was only 77%.

In the 15 lesions with IVUS MLA $\geq 6.0 \text{ mm}^2$, all but 1 (93%) showed FFR ≥ 0.80 , and FFR <0.75 was completely excluded. However, among 40 lesions with an IVUS MLA $<6.0 \text{ mm}^2$, 15 (38%) had FFR ≥ 0.80 , and 21 (58%) had FFR ≥ 0.75 .

An angiographic DS $>48\%$ was the best cutoff on ROC curve, but a poor predictor of FFR <0.80 (sensitivity 51%, specificity 75%, AUC: 0.654, 95% CI: 0.501 to 0.787, $p = 0.070$). An FFR <0.80 was demonstrated in 11 (38%) of 29 lesions with an angiographic DS $\leq 48\%$, and FFR ≥ 0.80 was seen in 6 (33%) of 18 lesions with DS $\leq 48\%$.

Treatment. Overall, 29 patients underwent PCI, and 1 patient underwent coronary artery bypass surgery at the discretion of the operator. Revascularization was performed in 18 (95%) of 19 lesions with FFR <0.75, 5 (71%) of 7 lesions with FFR 0.75 to 0.80, and 7 (29%) of 24 lesions with FFR ≥ 0.80 .

Discussion

The major findings of this study of intermediate LM lesions are the following: 1) IVUS-measured MLA within the LM was the independent determinant for both FFR <0.80 and

Table 3. Univariable Analysis to Predict Abnormal FFR

Variables	Prediction of FFR <0.80			Prediction of FFR <0.75		
	C-OR	95% CI	p Value	C-OR	95% CI	p Value
MLA within LM	0.312	0.164-0.593	<0.001	0.196	0.076-0.501	0.001
Plaque burden	1.095	1.031-1.164	0.003	1.142	0.050-1.241	0.002
Lesion length	1.192	1.038-1.368	0.013	1.102	0.981-1.237	0.102
Rupture	3.273	0.953-11.243	0.060	3.143	0.895-11.034	0.074
Angiographic DS	1.049	0.993-1.108	0.088	1.078	1.013-1.147	0.020
Lesion location	2.081	1.070-4.046	0.031	1.851	0.934-3.670	0.078
Male	0.511	0.127-2.057	0.345	0.663	0.149-2.947	0.590
Age	0.965	0.917-1.016	0.172	0.994	0.944-1.047	0.826
Diabetes mellitus	1.062	0.304-3.710	0.924	0.700	0.180-2.725	0.607
Hypertension	1.300	0.412-4.101	0.654	2.671	0.749-9.531	0.130
Smoker	2.701	0.816-8.945	0.104	2.062	0.579-7.347	0.264
Hyperlipidemia	1.167	0.324-4.200	0.814	0.765	0.203-2.889	0.693
Stable presentation	0.476	0.078-2.894	0.420	0.347	0.037-3.253	0.354

CI = confidence interval; C-OR = corrected odds ratio; DS = diameter stenosis; other abbreviations as in Table 2.

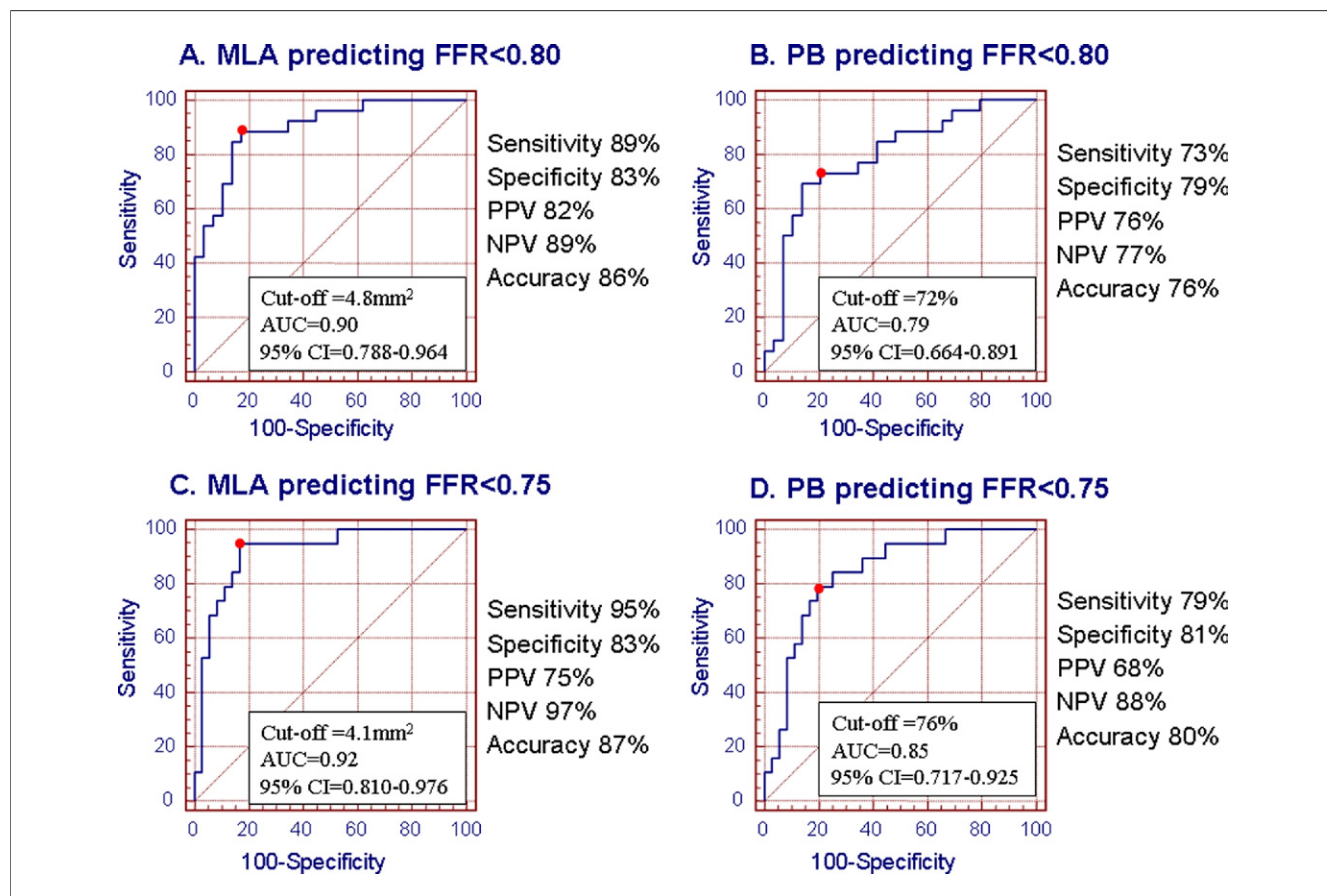


Figure 1. Cutoff Values and Diagnostic Accuracies

(A) Cutoff values and diagnostic accuracies of intravascular ultrasound-derived minimal lumen area (MLA) predicting fractional flow reserve (FFR) <0.80. (B) Cutoff values and diagnostic accuracies of plaque burden (PB) for FFR <0.80. (C) Cutoff values and diagnostic accuracies of MLA predicting FFR <0.75. (D) Cutoff values and diagnostic accuracies of plaque burden for FFR <0.75. AUC = area under the curve; CI = confidence interval; NPV = negative predictive value; PPV = positive predictive value.

FFR <0.75 at maximal hyperemia; 2) the best cutoff value to predict FFR <0.80 and FFR <0.75 were an IVUS MLA of 4.8 mm² and 4.1 mm², respectively; and 3) plaque rupture in the LM was frequent and independently affected the FFR and the FFR versus IVUS correlation.

Previous studies have demonstrated that FFR >0.75 to 0.80 was a strong predictor of favorable clinical outcomes in patients with intermediate LM disease (4–8). On the basis of FFR <0.75 and FFR ≥0.75, Jasti et al. (7) reported that the 38-month survivals were 100% versus 100% and event-free survival estimates were 100% versus 90%, respectively (all, *p* > 0.05). When treatment strategy of equivocal LM stenosis was determined by FFR <0.80 (bypass surgery) versus ≥0.80 (medical therapy), 5-year survival estimates were similar between surgical and nonsurgical groups (85.4% vs. 89.8%, *p* = 0.48), as were the 5-year event-free survival estimates (74.2% vs. 82.8%, *p* = 0.50) (9). Thus, FFR measurement is appropriate to identify patients with intermediate LM stenosis in whom deferral of revascular-

ization is associated with excellent survival and low event rates.

Despite the statistically significant correlation between angiographic DS and FFR as continuous variables in the current study, there was a large scatter; and there was no angiographic DS that accurately predicted an abnormal FFR, consistent with previous results (10,11). In the current study more than one-third of the lesions were misclassified with angiographic assessment alone.

Studies have differed on the cutoff value of the IVUS-derived MLA that identified a significant LM stenosis (7,12,13). With the mean minus 2 SDs of MLA measurements in patients with a normal LM, Fassa et al. (12) reported that an MLA >7.5 mm² seemed to be safe to defer revascularization. Furthermore, on the basis of the long-term outcomes, the best cutoff of the MLA for performing or deferring revascularization was 9.6 mm² by ROC (12). Nissen et al. (13) proposed an absolute area <9 mm² as a criteria for a significant LM stenosis. Compared with FFR

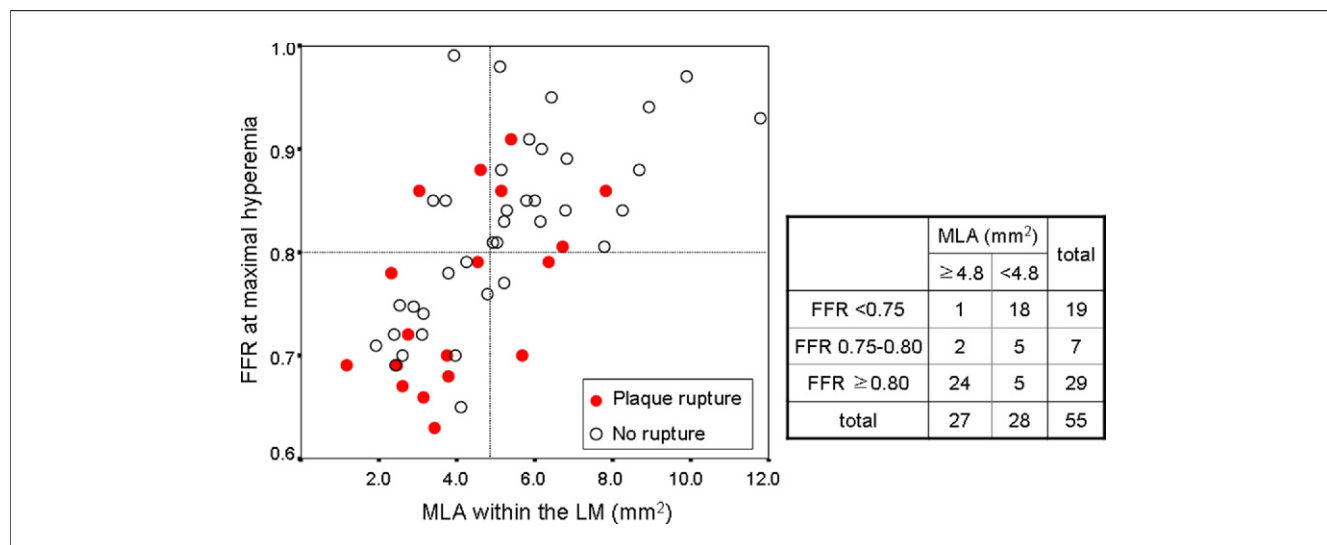


Figure 2. Correlation Between MLA and FFR

The lesions with plaque rupture are represented as **red circles**. LM = left main coronary artery; other abbreviations as in Figure 1.

as the “gold standard,” Jasti et al. (7) reported that an MLA of 5.9 mm² had the highest sensitivity and specificity (93% and 95%, respectively) for determining a significant LM stenosis.

In the current study, the cutoff value that best predicted an abnormal FFR was lower than previously suggested. Among 28 lesions with an IVUS MLA <4.8 mm², 23 (82%) had FFR <0.80, and 18 (64%) had FFR <0.75. Conversely, among 40 lesions with an IVUS MLA ≥6.0 mm², only 19 (48%) had FFR <0.75, and 25 (63%) had FFR <0.80. Thus, an MLA <6.0 mm² was less specific for predicting an abnormal FFR (a specificity of 48% for FFR <0.80 and a specificity of 42% for FFR <0.75), suggesting that with this criterion approximately 60% of lesions without functional significance would undergo PCI or surgery, perhaps unnecessarily. Even though the MLA ≥4.8 mm² excellently excluded FFR <0.80 in 89% of patients and FFR <0.75 in 96% of patients, normal FFR (≥0.80 and ≥0.75) was still observed in 18% and 36% of the lesions, respectively, with a smaller MLA <4.8 mm². Moreover, in the presence of plaque rupture, the diagnostic accuracy was only 77%. To avoid the wrong diagnosis in terms of functional significance, invasive FFR or noninvasive stress tests should precede the decision for treatment especially for the lesions with MLA <4.8 mm² or plaque rupture.

Recent studies have reported a worse correlation between IVUS and FFR in intermediate non-LM disease than was seen in LM lesions in the current study (17–19). Thus, the diagnostic accuracy of the MLA cutpoint seems to be better in LM lesions compared with the non-LM lesions. This might be explained by the simplicity of morphological characteristics of pure LM lesions, uniformly large vessel size, short lesion length, and lack of side branch and other

anatomical factors potentially affecting FFR. Additionally, studied patients had no regional wall motion abnormalities and mostly showed preserved left ventricular ejection fraction. Consistent amount of viable myocardium might contribute to minimize the influence on FFR.

The frequency of plaque rupture within the LM as a culprit lesion and the impact of plaque rupture on functional significance of stenosis have been unknown. The current data identified plaque rupture in 38% of patients with stable and unstable angina and suggested that plaque rupture independently affected FFR. However, further study is necessary to confirm the physiological effect of plaque rupture.

Study limitations. First, the current study included a relatively small number of patients with pure LM disease without significant downstream disease. Second, we excluded patients with significant LAD or left circumflex artery stenosis; this is a frequent problem in real practice. With the lack of validation with clinical outcomes, the current study assumed FFR to be the gold standard and investigated angiographic and IVUS morphological predictors for currently accepted cutoff of FFR. Clinical follow-up study with the new IVUS criteria should be performed in a large cohort to clarify the natural history of deferred lesions with the MLA ≥4.8 mm² and to support guidelines for revascularization strategy.

Conclusions

In pure LM disease, an IVUS-derived MLA <4.8 mm² is a useful criterion for predicting FFR <0.80.

Reprint requests and correspondence: Dr. Seung-Jung Park, Asan Medical Center, 388-1 Poongnap-dong, Songpa-gu 138-736, Seoul, South Korea. E-mail: sjpark@amc.seoul.kr.

REFERENCES

- Berger A, Botman KJ, MacCarthy PA, et al. Long-term clinical outcome after fractional flow reserve-guided percutaneous coronary intervention in patients with multivessel disease. *J Am Coll Cardiol* 2005;46:438-42.
- Wongpraparut N, Yalamanchili V, Pasnoori V, et al. Thirty-month outcome after fractional flow reserve-guided versus conventional multivessel percutaneous coronary intervention. *Am J Cardiol* 2005;96:877-84.
- Tonino PA, De Bruyne B, Pijls NH, et al. Fractional flow reserve versus angiography for guiding percutaneous coronary intervention. *N Engl J Med* 2009;360:213-24.
- Bech GJ, Droste H, Pijls NH, et al. Value of fractional flow reserve in making decisions about bypass surgery for equivocal left main coronary artery disease. *Heart* 2001;86:547-52.
- Lindstaedt M, Yazar A, Germing A, et al. Clinical outcome in patients with intermediate or equivocal left main coronary artery disease after deferral of surgical revascularization on the basis of fractional flow reserve measurements. *Am Heart J* 2006;152:e1-9.
- Jiménez-Navarro M, Hernández-García JM, Alonso-Briales JH, et al. Should we treat patients with moderately severe stenosis of the left main coronary artery and negative FFR results? *J Inv Cardiol* 2004;16:398-400.
- Jasti V, Ivan E, Yalamanchili V, Wongpraparut N, Leeser MA. Correlations between fractional flow reserve and intravascular ultrasound in patients with an ambiguous left main coronary artery stenosis. *Circulation* 2004;110:2831-6.
- Courtis J, Rodés-Cabau J, Larose E, et al. Usefulness of coronary fractional flow reserve measurements in guiding clinical decisions in intermediate or equivocal left main coronary stenoses. *Am J Cardiol* 2009;103:943-9.
- Hamilos M, Muller O, Cuisset T, et al. Long-term clinical outcome after fractional flow reserve-guided treatment in patients with angiographically equivocal left main coronary artery stenosis. *Circulation* 2009;120:1505-12.
- Leesar MA, Mintz GS. Hemodynamic and intravascular ultrasound assessment of an ambiguous left main coronary artery stenosis. *Catheter Cardiovasc Interv* 2007;70:721-30.
- Abizaid AS, Mintz GS, Abizaid A, et al. One-year follow-up after intravascular ultrasound assessment of moderate left main coronary artery disease in patients with ambiguous angiograms. *J Am Coll Cardiol* 1999;34:707-15.
- Fassa AA, Wagatsuma K, Higano ST, et al. Intravascular ultrasound-guided treatment for angiographically indeterminate left main coronary artery disease: a long-term follow-up study. *J Am Coll Cardiol* 2005;45:204-11.
- Nissen SE, Yock P. Intravascular ultrasound: novel pathophysiological insights and current applications. *Circulation* 2001;103:604-16.
- Pijls NH, van Schaardenburgh P, Manoharan G, et al. Percutaneous coronary intervention of functionally nonsignificant stenosis: 5-year follow-up of the DEFER Study. *J Am Coll Cardiol* 2007;49:2105-11.
- Pijls NH, De Bruyne B, Peels K, et al. Measurement of fractional flow reserve to assess the functional severity of coronary artery stenoses. *N Engl J Med* 1996;334:1703-8.
- Mintz GS, Nissen SE, Anderson WD, et al. American College of Cardiology Clinical Expert Consensus Document on Standards for Acquisition, Measurement and Reporting of Intravascular ultrasound Studies (IVUS). A report of the American College of Cardiology Task Force on Clinical Expert Consensus Documents. *J Am Coll Cardiol* 2001;37:1478-92.
- Kang SJ, Lee JY, Ahn JM, et al. Validation of intravascular ultrasound-derived parameters with fractional flow reserve for assessment of coronary stenosis severity. *Circ Cardiovasc Interv* 2011;4:65-71.
- Nam CW, Yoon HJ, Cho YK, et al. Outcomes of percutaneous coronary intervention in intermediate coronary artery disease: fractional flow reserve-guided versus intravascular ultrasound-guided. *J Am Coll Cardiol Intv* 2010;3:812-7.
- Lee CH, Tai BC, Soon CY, et al. New set of intravascular ultrasound-derived anatomic criteria for defining functionally significant stenoses in small coronary arteries (results from Intravascular ultrasound Diagnostic Evaluation of Atherosclerosis in Singapore [IDEAS] study). *Am J Cardiol* 2010;105:1378-84.

Key Words: fractional flow reserve ■ intravascular ultrasound ■ left main coronary artery.