

Patent Foramen Ovale Closure With the SeptRx Device

Initial Experience With the First “In-Tunnel” Device

Wibke J. Zimmermann, MD, Corinna Heinisch, MD, Nicolas Majunke, MD,
Stephan Staubach, MD, Scott Russell, Nina Wunderlich, MD, Horst Sievert, MD

Frankfurt, Germany

Objectives The purpose of this study was to evaluate the safety and effectiveness of the SeptRx patent foramen ovale (PFO) closure device (SeptRx, Inc., Fremont, California).

Background A PFO is a relatively common remnant of the fetal circulation that can be associated with cryptogenic stroke, transient ischemic attack, migraine, or decompression sickness. Percutaneous PFO closure with different devices has been performed for many years. However, most of the common devices leave a relatively large amount of material in the left and right atria. The SeptRx PFO device (SeptRx, Inc.) is the first PFO closure device designed to fit directly into the pocket of the PFO.

Methods From July 2006 to May 2007, 13 patients between 18 and 65 years of age with a history of cryptogenic stroke or transient ischemic attack were included into this first-in-man trial. All patients received 100 mg aspirin and 75 mg clopidogrel for 6 months. Follow-up was done at 1 and 6 months after procedure with transesophageal echocardiography and transcranial Doppler.

Results In 11 of 13 patients, PFO closure with the SeptRx device was successfully performed. In 2 patients, PFO closure with this device was not possible due to the anatomy of the PFO; 1 device was retrieved before release, and the other was recaptured with a snare. After 30 days, 6 of the 11 PFOs were closed; after 6 months, all were closed. No adverse events occurred.

Conclusions The SeptRx PFO closure device appears to be safe and effective. The advantage of this occluder is that there is only minimal foreign material on the left and right sides of the interatrial septum. This is the first such “in-tunnel” PFO closure device. (J Am Coll Cardiol Intv 2010;3:963–7)

© 2010 by the American College of Cardiology Foundation

From the CardioVascular Center, Sankt Katharinen, Frankfurt, Germany. Dr. Russell is an employee of SeptRx, Inc. Dr. Sievert has received consulting fees, travel expenses, and/or study honoraria from Abbott, Access Closure, AGA, Angiomed, Ardian, Arstasis, Avinger, Boston, Bridgepoint, CardioKinetix, CardioMEMS, Coherex, Cordis, CSI, Edwards, EndoCross, EndoTex, ev3, FlowCardia, Gore, Guidant, Invatec, Lumen Biomedical, Kensey Nash, Kyoto Medical, Medtronic, Nitinol Devices and Components (NDC), NMT, OAS, Occlutech, Osprey, Ovalis, Pathway, pfm, PendraCare, Percardia, Remon, Rox Medical, Sadra, Sorin, Spectranetics, SquareOne, St. Jude, Terumo, Viacor, Velocimed, Xtent, Cardiokinetix, Access Closure, Coherex, Velocimed, CoAptus, and Lumen Biomedic. All other authors report that they have no relationships to disclose.

Manuscript received March 30, 2010, accepted April 5, 2010.

A patent foramen ovale (PFO) is a tunnel-like defect bounded by the septum primum and septum secundum connecting the right and left atria (1). The length of the tunnel can vary widely, according to Marshall and Lock (2), between 2.4 and 19.5 mm. In the fetal period, the foramen ovale is a physiological pathway from the right to the left atrium for blood to bypass the lungs. In the first days after birth, the foramen ovale should close, but in 25% to 30% of people it does not fully close (3). This can lead to stroke or transient ischemic attack (TIA) by providing a right to left shunt for the passage of emboli into the arterial circulation. Patent foramen ovals are also found more frequently in patients suffering from migraine with or without aura (4–6) and those with decompression sickness (7).

Percutaneous PFO closure has been successfully performed since the 1980s with different kinds of devices (8). Closure, however, might be complicated by thrombus formation on the device or atrial fibrillation (9).

Methods

Study design. The feasibility study was designed as a prospective, single-center, first-in-human trial. The study was sponsored by Nitinol Devices and Components (NDC, Fremont, California). It was approved by the local ethics committee, and all patients provided written informed consent.

Patients with a history of cryptogenic stroke or TIA between 18 and 65 years of age were included in the trial. The PFO size had to be between 5 and 12 mm in width and between 3 and 30 mm in length, as evaluated by balloon sizing. Patients with additional atrial septal defects, other heart abnormalities, or history of arrhythmia were excluded, as were patients with active endocarditis or thrombus near the PFO.

Tables 1, 2, and 3 show the patient demographic data, the PFO demographic data, and the qualifying event for inclusion in the study.

Mean PFO diameter in this study was 7.6 mm (\pm 2.1 mm SD; range 4.9 to 11.3 mm). Four patients were found to have an atrial septum aneurysm. During follow-up, 2 of these 4 had a residual shunt—1 small, and the other moderate in size. None of them had a multifenestrated septum. All PFOs had a diameter between 5 and 12 mm. One patient had to be excluded because the tunnel was shorter than 5 mm, and another 1 had to be excluded because the tunnel was longer than 12 mm.

Device and implantation technique. At the time of device implantation, all patients were given heparin, antibiotics, aspirin (100 mg), and clopidogrel (75 mg). The PFO balloon sizing was performed according to standard tech-

Age, yrs	52 \pm 13
Gender	46% male
Risk factors, n	
History of smoking	2
History of hypertension	6
History of hypercholesterolemia	2
History of deep vein thrombosis	0
History of diabetes mellitus	1 with gestation diabetes mellitus
History of arrhythmia	0
Concomitant diseases, n	
History of chronic heart failure	0
History of migraine	0
History of gastrointestinal bleeding	0
History of COPD	0
COPD = chronic obstructive pulmonary disease.	

niques. Transesophageal echocardiography and fluoroscopy were performed during the implantation.

The SeptRx PFO closure device (SeptRx, Inc., Fremont, California) consists of a laser-cut, electropolished, self-expanding Nitinol frame with flexible anchor struts at the top of the device, which uncoil from their curved shape to adapt to a variety of PFO tunnel lengths.

At the base of the device are additional anchors, which are designed to grip the edge of the PFO tunnel on the right atrial side. Only 1 size of the SeptRx device (device width: 14 mm, device length: 14 mm) was used in this study. Both the left and right atrial anchors are surrounded by a fine coil of tantalum for radiopacity. The interior of the device contains a fine-wire braided Nitinol mesh (NDC). The mesh is intended to stimulate the body's natural adhesion response for permanent closure of the PFO, and it also provides an immediate barrier to the conduction of emboli before permanent closure (Fig. 1).

The device is delivered over a guidewire through the inferior vena cava to the right atrium and across the PFO. The delivery system is compatible with a 0.035-inch guidewire and deliverable through a 9-F sheath. The device is connected to the delivery system by 2 positive "paddle" locks. These paddle locks ensure full control of the SeptRx implant (SeptRx, Inc.) until it is released by a simple thumbscrew release mechanism. The body of the delivery system is constructed of coaxial flexible tubes that provide excellent torque control for precise positioning of the device. The device might be recaptured into the original delivery sheath at any time of the procedure for repositioning or recovery.

Figure 2 demonstrates the SeptRx device with transesophageal echocardiography during the 6-month follow-up. Figures 3 and 4 demonstrate the implantation steps on fluoroscopy.

Table 2. PFO Morphology (n = 13)

PFO mean diameter (mm)	7.6 ± 2.1; 4.9–11.3
Atrial septal aneurysm (n)	4
Septum excursion range (mm)	7.5 ± 1.4; 6.6–9.0
Valvula eustachii (n)	4

PFO = patent foramen ovale.

Management after implantation. All patients received 100 mg aspirin and 75 mg clopidogrel for 6 months after implantation. They were advised to take endocarditis prophylaxis in case of exposure for 6 months. Patients were seen for follow-up at 30 days and 6 months after the implantation. Follow-up investigations included physical examination, electrocardiogram, transcranial Doppler, and transesophageal echocardiography with a contrast bubble study.

Results

Device implantation was successful in 11 of 13 patients. One patient had a very short tunnel, and after implantation the device was mostly sitting in the right atrium, so it was recaptured with a snare. This patient received an Amplatzer PFO occluder (AGA Medical Corp., Plymouth, Minnesota). The other patient had a very long tunnel, and it was not possible to place the SeptRx device correctly, so it was recaptured before release, and the PFO was closed with a Premere occluder (St. Jude Medical, St. Paul, Minnesota). **Closure rates.** At the 30-day follow-up, 5 patients (45%) presented with a residual shunt. Four of them had a minimal shunt (5 to 10 bubbles), and 1 had a moderate shunt (10 to 30 bubbles). The 6-month follow-up showed that all PFOs were closed.

Adverse events. During the 6 months of follow-up, no deaths, no strokes, no TIAs, no thrombus formation, no arrhythmias, no infections or hemopericardium, and no other serious adverse events occurred.

Discussion

Numerous transcatheter PFO closure systems are commercially available or under investigation. Some of the double umbrella devices leave a relatively large amount of foreign material in the atria, which can lead to thrombus formation on the device (9,10). We reported in a study with 1,000 patients that the incidence of thrombus formation is 2% (9). Furthermore, distortion of the septum due to a wire might be the cause of atrial fibrillation in some patients.

Table 3. Qualifying Event

History of stroke	5
History of transient ischemic attack	7
History of decompression sickness	1

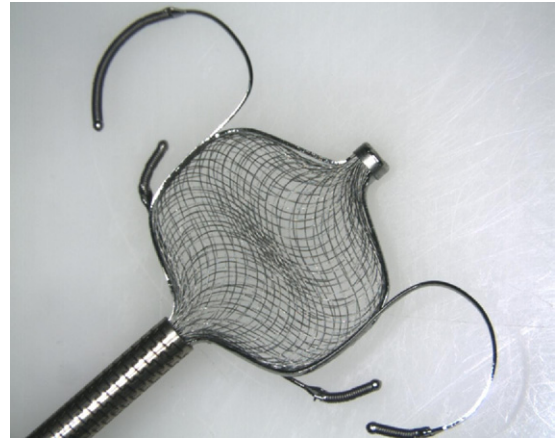


Figure 1. The SeptRx Device Attached to Its Delivery System

The longer anchors are on the left atrial side and are designed to uncoil to accommodate a range of patent foramen ovale (PFO) tunnel lengths. The interior of the device contains a fine-wire braided Nitinol mesh, which provides an immediate barrier to the conduction of emboli and is intended to stimulate the body's natural adhesion response for permanent closure of the PFO.

One of the advantages of the SeptRx device is the minimal material in the left atrium. So far, no thrombus formation has occurred, and the unique design of the device might help to minimize chronic complications such as thrombus formation or atrial fibrillation. A few other new devices are designed to minimize the incidence of thrombus formation. The BioSTAR device (NMT Medical, Boston, Massachusetts), reported by Mullen et al. (11), is a bioabsorbable septal repair device that is mostly replaced with healthy native tissue. According to the authors, 90% to 95%

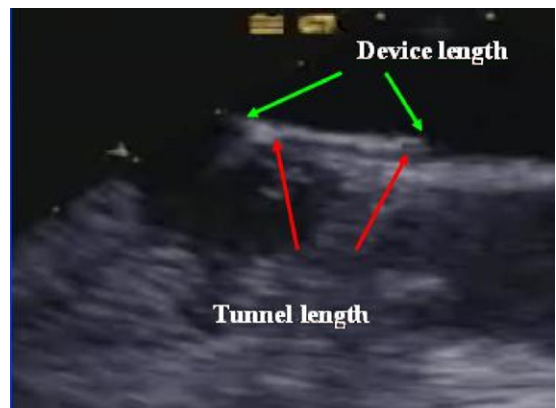


Figure 2. Transesophageal Echocardiography 6 Months After PFO Closure

The device is sitting with at least two-thirds of its length in the tunnel. This is minimizing the material in the left atrium. During follow-up, Valsalva maneuver was done. Abbreviation as in Figure 1.

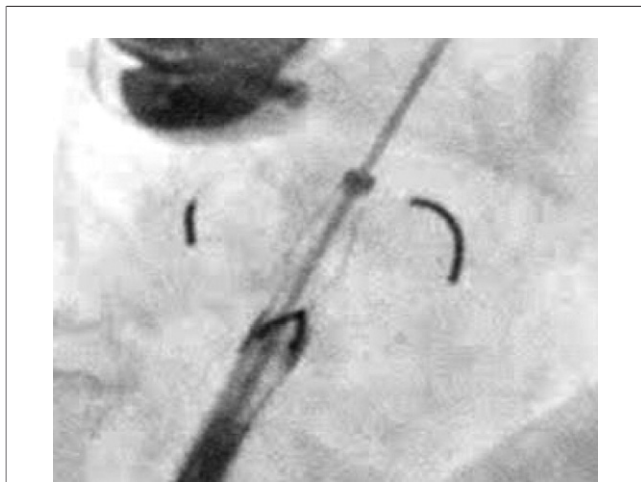


Figure 3. Fluoroscopy During Implantation Steps

The left atrial anchors are liberated from the delivery sheath, but the right atrial anchors are still inside. The right atrial anchors will first deflect inward as the proximal end of the device enters the tissue; then, the left atrial anchors will begin to unfurl as they engage with septum secundum.

of the device is absorbed, and this could also help to minimize the possibility of thrombus formation.

The Premere device has an open architecture and no fabric covering on the left atrial side, which could reduce the risk for thrombus formation as well. During the CLOSEUP trial, no thrombus formation was reported by Büscheck *et al.* (12).

Another advantage of the SeptRx device is that it does not limit future transeptal puncture through the septum to the left atrium if it is needed. Instead of covering both sides of the septum with an umbrella, the SeptRx device sits almost entirely in the tunnel.

According to Alaeddini *et al.* (13), in a study with 71 patients, 5 patients (7%) presented with atrial fibrillation or flutter. The devices used for the study were the CardioSEAL (NMT Medical) (28 mm or 33 mm) and the Amplatzer (AGA Medical Corp.). Atrial fibrillation occurred more often in patients with a larger device. Leaving only minimal material in the left atrium, the SeptRx device could possibly reduce the risk for atrial fibrillation.

Although only 11 patients were treated with the SeptRx device, the 100% closure rate and no major adverse events are very promising findings. In 2009, von Bardeleben *et al.* (14) published a study with 357 patients undergoing PFO closure with 3 different devices (199 Amplatzer, 48 STARFlex [NMT Medical], and 110 Helex [W. L. Gore and Assoc., Flagstaff, Arizona]). Five of the STARFlex patients (10.4%) developed a thrombus at the device. The overall residual shunt rate at 6-month follow-up was 7.6%. Luermans *et al.* (15) reported 83 patients (63 STARFlex and 20 Amplatzer) in which 11 (17.4%) of the STARFlex patients developed atrial ar-

rhythmia after the implantation. Residual shunt rate was 5.7% in this study. Taaffe *et al.* (16) reported a comparison of 220 Amplatzer, 220 STARFlex, and 220 Helex (W. L. Gore and Assoc.) implantations. They found thrombus formation in 8 STARFlex patients and atrial arrhythmia in 3 Amplatzer, 2 STARFlex, and 2 Helex patients. The publication of Slavin *et al.* (17) presented the results of 131 patients undergoing PFO closure, 101 with the Amplatzer device and 30 with the CardioSEAL (NMT Medical) device. Thrombus formation at the device occurred in 6 of the CardioSEAL patients. The residual shunt rate at 6-month follow-up was 10.6%. In a study with 128 Helex occluders, Billinger *et al.* (18) found the development of thrombus formation on the device in 9 patients and atrial arrhythmia in 2 patients. A residual shunt existed at 6-month follow-up in 15% and after 1 year in 11%.

These are the results of the small, prospective first-in-man trial. This year, a second trial with the SeptRx device will be started, hopefully reproducing these good results.

Conclusions

This study showed that PFO closure with the SeptRx device is technically feasible and safe. Neither device- nor procedure-related adverse events occurred, and PFO closure was achieved in 100% of the patients.

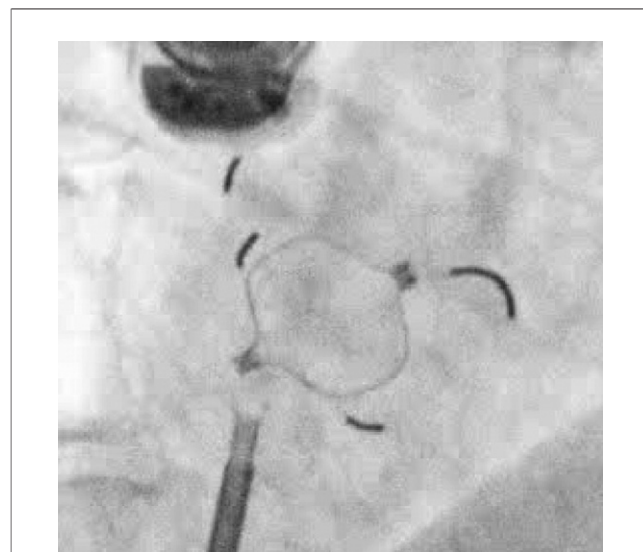


Figure 4. The SeptRx Device Completely Released From Its Delivery System

If the SeptRx implant is not satisfactorily placed in the patent foramen ovale, it can be recaptured into the Mullins sheath, and the deployment and positioning processes can be repeated. After implantation contrast injection was done.

Reprint requests and correspondence: Dr. Horst Sievert, CardioVascular Center Frankfurt, Seckbacher Landstrasse 65, 60389 Frankfurt, Germany. E-mail: horstsievertmd@aol.com.

REFERENCES

1. Momma K, Ito T, Ando M. In situ morphology of the foramen ovale in the fetal and neonatal rat. *Pediatr Res* 1992;32:669-72.
2. Marshall AC, Lock JE. Structural and compliant anatomy of the patent foramen ovale in patients undergoing transcatheter closure. *Am Heart J* 2000;140:303-7.
3. Hagen PT, Scholz DG, Edwards WD. Incidence and size of patent foramen ovale during the first 10 decades of life: an autopsy study of 965 normal hearts. *Mayo Clin Proc* 1984;59:17-20.
4. Kimmelstiel C, Gange C, Thaler D. Is patent foramen ovale closure effective in reducing migraine symptoms? A controlled study. *Catheter Cardiovasc Interv* 2007;69:740-6.
5. Anzola GP, Frisoni GB, Morandi E, Casilli F, Onorato E. Shunt-associated migraine responds favorably to atrial septal repair: a case-control study. *Stroke* 2006;37:430-4.
6. Sievert H, Horvath K, Zadan E, et al. Patent foramen ovale closure in patients with transient ischemia attack/stroke. *J Interv Cardio* 2001;14:261-6.
7. Torti SR, Billinger M, Schwerzmann M, et al. Risk of decompression illness among 230 divers in relation to the presence and size of patent foramen ovale. *Eur Heart J* 2004;25:1014-20.
8. Krumsdorf U, Keppeler P, Horvath K, Zadan E, Schrader R, Sievert H. Catheter closure of atrial septal defects and patent foramen ovale in patients with an atrial septal aneurysm using different devices. *J Interv Cardiol* 2001;14:49-55.
9. Krumsdorf U, Ostermayer S, Billinger K, et al. Incidence and clinical course of thrombus formation on atrial septal defect and patent foramen ovale closure devices in 1,000 consecutive patients. *J Am Coll Cardiol* 2004;43:302-9.
10. Anzai H, Child J, Natterson B, et al. Incidence of thrombus formation on the CardioSEAL and the Amplatzer interatrial closure devices. *Am J Cardiol* 2004;93:426-31.
11. Mullen MJ, Hildick-Smith D, De Giovanni JV, et al. BioSTAR Evaluation Study (BEST): a prospective, multicenter, phase I clinical trial to evaluate the feasibility, efficacy, and safety of the BioSTAR bioabsorbable septal repair implant for the closure of atrial-level shunts. *Circulation* 2006;114:1962-7.
12. Büscheck F, Sievert H, Kleber F, et al. Patent foramen ovale using the Premere device: the results of the CLOSEUP trial. *J Interv Cardiol* 2006;19:328-33.
13. Alaeddini J, Feghali G, Jenkins S, Ramee S, White C, Abi-Samra F. Frequency of atrial tachyarrhythmias following transcatheter closure of patent foramen ovale. *J Invasive Cardiol* 2006;18:365-8.
14. von Bardeleben RS, Richter C, Otto J, et al. Long term follow up after percutaneous closure of PFO in 357 patients with paradoxical embolism: difference in occlusion systems and influence of atrial septum aneurysm. *Int J Cardiol* 2009;134:33-41.
15. Luermans JG, Post MC, Plokker HW, Ten Berg JM, Suttrop MJ. Complications and mid-term outcome after percutaneous patent foramen ovale closure in patients with cryptogenic stroke. *Neth Heart J* 2008;16:332-6.
16. Taaffe M, Fischer E, Baranowski A, et al. Comparison of three patent foramen ovale closure devices in a randomized trial (Amplatzer versus CardioSEAL-STARFlex versus Helex occluder). *Am J Cardiol* 2008;101:1353-8.
17. Slavin L, Tobis JM, Rangarajan K, Dao C, Krivokapich J, Liebeskind DS. Five-year experience with percutaneous closure of patent foramen ovale. *Am J Cardiol* 2007;99:1316-20.
18. Billinger K, Ostermayer SH, Carminati M, et al. HELEX Septal Occluder for transcatheter closure of patent foramen ovale: multicentre experience. *EuroIntervention* 2006;1:465-71.

Key Words: closure device ■ occluder ■ patent foramen ovale.