

patterns and improve access to newer therapies for MR, such as MitraClip.

CRT-700.52

Optimal Mitral Valve-in-valve Sizing and Positioning Using Braile Inovare[®] Transcatheter Valve: An In Vitro Analysis



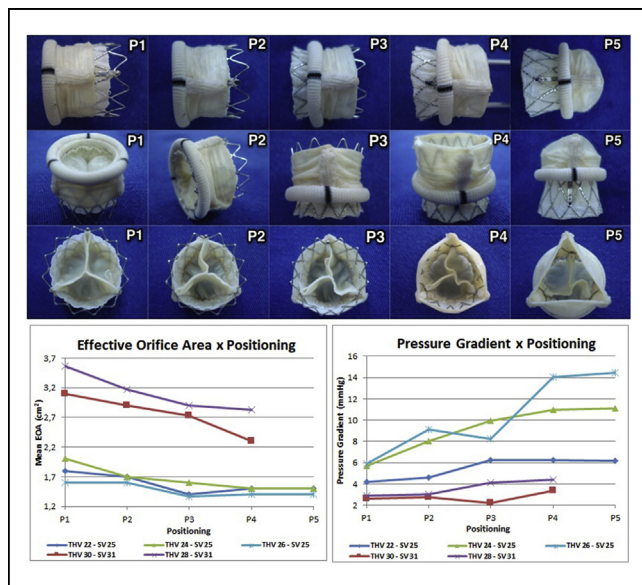
Giovanni Braile Sternieri,¹ Danilo Antonio da Silva,² Vinicius Ladeia Semenzim,³ Glaucia Frazzato,³ Sofia Braile,⁴ Valeria Braga Braile,³ Honório Palma,⁵ Domingo Marcelino Braile³
¹PUC-Campinas, Campinas, Brazil; ²Braile biomédica, São José do rio preto, Brazil; ³Braile biomédica, Sao Jose do Rio Preto, Brazil; ⁴UNOESTE, Presidente Prudente, Brazil; ⁵Universidade de São Paulo, São Paulo, Brazil

BACKGROUND Transcatheter Heart Valves (THV) are the most innovative solutions for heart valve diseases. Valve-in-valve (ViV) procedure is a good alternative to reoperation, once 20-35% of mitral surgery need reintervention within 10 years and this kind of procedure is risky. The appropriate positioning for mitral ViV implantation using the bioprosthesis as a reference is not well defined and there are few studies exploring this subject. Therefore, this study prospectively the influence on in vitro hydrodynamic performance of Inovare[®] THV (Braile Biomédica, Brazil), a balloon expandable one, in regard to mitral ViV implantation in different depths and oversizing.

METHODS Inovare[®] THV of 22, 24, 26, 28 and 30 mm were implanted within four Braile's surgical valve (SV) sizes (25, 27, 29 and 31 mm) on a pulse duplicator, testing different hemodynamic conditions. Oversizing from 4 to 24% and 5 different implantation depths were considered.

RESULTS Results show an optimal deployment depth range. Deeper positioning (ventricular) shows better hemodynamic performance in comparison to upper positioning (atrial), besides an appropriate oversizing of Inovare[®] THV related to Braile bioprosthesis is a determinant factor to define the best depth range implantation.

CONCLUSION Considering that there are no previous reports for mitral ViV with Inovare[®] THV, these findings may encourage researchers to study other correlations concerning mitral ViV, extending these analyzes for better and safer clinical results.



CRT-700.53

Immediate Hemodynamic & Echocardiographic Results of Percutaneous Transvenous Mitral Commissurotomy in Patients of Symptomatic Mitral Stenosis with Mitral Annular Calcification



Toufiqur Rahman, MD
 National Institute of Cardiovascular Diseases, Dhaka, Bangladesh

OBJECTIVES To see the immediate hemodynamic and echocardiographic results of Percutaneous Transvenous Mitral Commissurotomy (PTMC) in patients with mitral stenosis with mitral annular calcification.

BACKGROUND Rheumatic mitral stenosis is a very common problem in our population having an incidence of 54 percent among rheumatic heart disease with a female preponderance of 2:1. Percutaneous balloon mitral commissurotomy is appealing because the mechanism of valve dilation closely parallels the mechanism of surgical mitral commissurotomy. Mitral annular calcification (MAC) is degenerative, fibrous calcification of the mitral valve annulus. Wilkins scoring system does not examine MAC, which is characterized by calcium and lipid deposition within the annular fibrosa of the mitral valve and might independently influence the PTMC result .

METHODS A prospective study was done during the period of August 2003 to June 2017. One Thousand Nine hundred and eighty (1980) patients with rheumatic mitral stenosis who underwent PTMC were evaluated clinically, by echocardiography and by catheter, during and after procedure. Out of 1980 patients, 120 patients had mitral annular calcification (Group-1) and 1860 patients had no mitral annular calcification (Group-2).

RESULTS Most of the population are female, 70% in Group-1 and 78% in group-2. After PTMC mean mitral valve area increased from 0.80 ± 0.11 cm² to 1.46 ± 0.27 cm² as measured by echocardiography in group-1 and from 0.85 ± 0.32 cm² to 1.81 ± 0.33 cm² in group-2. Mitral valve gradient reduced to 11.63 ± 4.15 mm Hg from 32.46 ± 03.94 mm Hg after PTMC in group-1 and 10.45 ± 3.76 mm Hg from 26.64 ± 04.12 mm Hg after PTMC in group-2.

CONCLUSION PTMC is an effective procedure for patients with mitral annular calcification, but the result is inferior to patients with no mitral annular calcification .So, mitral annulus evaluation may be considered in the echocardiographic assessment of the mitral apparatus prior to PTMC.

OTHER

CRT-700.54

Alcohol Septal Ablation Produces Similar Changes to CBC as Atherosclerotic Myocardial Infarction but Platelet Counts Are Not Elevated. Is There Less Inflammation With ASA?



Billy J. Mullinax, Mira Patel, Alex Canova, Ashley Waring, Christopher Neilsen, Valerian Fernandes
 Medical University of South Carolina, Charleston, SC

OBJECTIVES To study blood cell count changes after alcohol-induced septal infarct in Hypertrophic Obstructive Cardiomyopathy (HOCM) patients.

BACKGROUND Atherosclerotic myocardial infarction (MI) is a proinflammatory and prothrombotic state associated with neutrophilic leukocytosis, anemia, and increased platelet count and platelet size. The degree of leukocytosis correlates with infarction size and, together with increased platelets, amplifies myocardial inflammation. Alcohol Septal Ablation (ASA) produces a targeted infarction in the hypertrophied septum to reduce left ventricular outflow obstruction. The inflammatory and thrombotic effects of this iatrogenic alcohol-induced infarction have not been studied.

METHODS We evaluated 215 consecutive patients who underwent ASA with pre- and post-ASA hemoglobin, WBC count, platelet counts, and troponin.

RESULTS A total of 215 patients (age 61.37 ± 13.18, 91M, 124F) who underwent ASA were included in the study. Alcohol (2.10 ± 0.69cc) was injected into a targeted septal artery, producing a peak troponin of 53.46 ± 48.80 ng/ml. After ASA, WBC increased from 7.07 ± 2.03 to 8.22 ± 2.57 (p<0.001), hemoglobin decreased from 13.30 ± 1.82 to 12.22 ± 1.98 (p<0.001), and platelet counts decreased from 200 ± 56 to 177 ± 48 (p <0.001). Different tertiles of hemoglobin, WBC, and platelet counts showed no correlation to peak troponin values following ASA. The volume of alcohol injected did not affect the pre- and post-ASA hemoglobin, WBC, and platelet counts.

CONCLUSIONS Compared to atherosclerotic MI, alcohol-induced infarction also leads to an increase in WBC count and anemia, but unlike atherosclerotic MI there is a reduction in platelet count. This suggests that ASA produces a similar inflammatory response with a